

EDITORIAL

H. Partsch (Vienna, Austria) **Page 236**

PHLEBOLOGY

Radiofrequency ablation of the incompetent saphenous vein—lessons learned **Page 237**

R. F. Merchant (Reno, USA)

Nutcracker syndrome **Page 246**

O. Hartung (Marseille, France)

**Shave therapy for venous ulcers
—a review and current results** **Page 253**

H. J. Hermanns, P. Waldhausen (Krefeld, Germany)

**Amniotic membrane: an innovative treatment
of refractory vascular ulcers?** **Page 259**

F. Pesteil, M. Drouet, M.-C. Rousanne, P. Lacroix (Limoges, France)

ABOUT NEW ARTICLES AND BOOKS

A review by Stavros K. Kakkos **Page 266**

A review by Michel Perrin **Page 269**

CONGRESS

Congress and conference calendar **Page 270**

Dear Readers,

Fascinating topics are presented in this issue of Phlebology.

Robert F. Merchant, USA, who is one of the pioneers of catheter-based radiofrequency ablation as a less invasive alternative to conventional vein stripping, gives very useful recommendations for improving the results of this method by using modifications of the original technique and innovations in equipment. The material presented is based on an outstanding review of clinical trials comparing different methodologies.

The nutcracker syndrome is a clinical entity not well known to most phlebologists. **Olivier Hartung** from Marseille gives a comprehensive overview of this compression syndrome, in which the left renal vein is compressed between the aorta and the superior mesenteric artery. This pathology may be compared with other venous entrapment syndromes, like May-Thurner syndrome.

Hans Joachim Hermanns and Peter Waldhausen from Germany have written an article of practical importance, which impressively shows that surgery offers very promising ways to treat recalcitrant leg ulcers. Impressive improvement can be achieved even in seemingly hopeless cases. The main emphasis is placed on local shaving of ulcers together with mesh grafting.

The last contribution, by **Francis Pesteil** and co-workers, France, considers poorly healing leg ulcers, and shows that amniotic membrane can be used as a promising new dressing for local treatment of recalcitrant ulceration.

Happy reading!

Hugo Partsch, MD



Radiofrequency ablation of the incompetent saphenous vein— lessons learned

Robert F. MERCHANT

The Reno Vein Clinic, Reno, Nevada

INTRODUCTION

Investigations into the therapeutic use of radiofrequency (RF) energy in man occurred as early as the late 19th and early 20th centuries. Technological advances increased interest in RF applications. Because of its precise control of energy delivery and reliability, RF energy has been used for decades in neurosurgical techniques.¹ By the 1980s cardiac arrhythmias were being treated with RF devices.² Usage expanded to include treatment of various malignancies (including hepatic, renal, musculoskeletal, breast, lymph, spleen, pulmonary),^{3,4} as well as ophthalmologic maladies, gastric reflux, sleep apnea, and aesthetic dermatological conditions.^{5,6} Berjano reported that the number of scientific papers published on the topic of therapeutic RF energy use increased from 19 in 1990 to 825 in 2005.⁵ As a less invasive alternative to vein stripping for elimination of saphenous vein reflux, the percutaneous catheter-based radiofrequency Closure[®] procedure (VNUS Medical Technologies, San Jose, CA) was introduced in Europe in 1998 and in the U.S. in 1999.

Following initial experience with the Closure[®] procedure and early technique modifications, it became clear that reflux at the saphenofemoral junction (SFJ) could be eliminated by obliteration of the great saphenous vein in the thigh without resorting to dissection and ligation of all contributing branches near the saphenofemoral junction,^{7,8} thus eliminating the need for a groin incision and potential for minor and even major complications that can occur following traditional ligation and stripping procedures, and leaving intact venous return and lymphatic drainage from the abdominal wall and lower extremity. The validity of this strategy has been borne out by several published mid-term reports.⁹⁻¹² Pichot¹¹ coordinated an extensive two-year follow-up ultrasound evaluation study from five VNUS Registry centers. The results showed that 58/63 (92.1%) treated GSV segments remained free of reflux. Junctional tributary reflux was seen in 7/63 (11.1%) limbs, four of

Keywords:

radiofrequency ablation, endovenous thermal ablation, venous closure procedure, radiofrequency perforator vein ablation, closureFAST, saphenous vein ablation

Phlebology. 2009;16(2):237-245.

which were associated with the SFJ as the sole source of reflux. Neovascularization was not observed in any treated limbs. More recently, Closure® equipment innovations and technique modifications have contributed to reduced procedure times while maintaining efficacy and low rates of complications.

TECHNIQUE

Unlike earlier attempts to obliterate the saphenous vein by diathermy, the endovenous Closure® procedure uses radiofrequency energy to heat the vein wall. The ClosurePLUS™ catheter employs intralumenally positioned bipolar electrodes located at the tip in contact with the vein wall. Electrical current flowing between the electrodes through the vein wall tissue generates heat by a phenomenon called “resistive heating”. The new ClosureFAST™ catheter (illustrated in Figure 1) utilizes radiofrequency energy to heat a 7 cm long element near the tip resulting in direct conduction to the vein wall. For satisfactory transfer of energy, the electrodes or the element must be in direct contact with the vein wall. The heating causes a physical shortening of the vein wall’s collagen fibrils in a mostly uniform manner, primarily in the subendothelial layers.¹³ A recent report by Schmedt et al corroborates this finding.¹⁴ The vein narrows while at the same time denatured blood proteins congeal to obliterate the vein lumen. The entire treated vein is affected by this process much like soft boiling an egg. Over the next several months, usually ten to twelve, and certainly by two years, the vein fibroses and is seen to vanish on duplex ultrasound (DUS) in over 86% of cases.¹¹

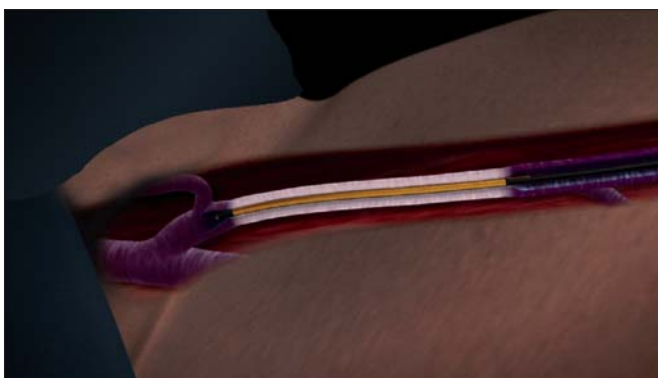


Figure 1. The ClosureFAST™ catheter distal section, which contains a 7 cm long heating element, is depicted heating the GSV vein segment starting approximately 2 cm below the SFJ. (GSV – great saphenous vein; SFJ – saphenofemoral junction)

The ClosurePLUS™ procedure is controlled by a computerized generator (RF1 or RF2) which monitors electrode temperature and adjusts energy levels to achieve a constant heating of the vein wall at a user-selectable temperature, typically 85° or 90° ± 3°C. During heating, the catheter is withdrawn from the vein typically at a rate of 2-4 centimeters per minute. For the ClosureFAST™ procedure, the newer RF2 generator (which can be used with all VNUS catheters) controls the heating element at 120°C for a predetermined 20-second period that can be manually interrupted at any moment by the operator. The major steps of the technique as currently practiced at the Reno Vein Clinic are as follows:

Patient anesthesia: Choice of anesthesia is a matter between the physician and the patient. However, the procedure itself is well suited to local anesthesia or regional field block such as a femoral nerve block. General anesthesia has at least one drawback: the inability of the anesthetized patient to communicate nerve pain which might be the result of the heat produced by the catheter coming into proximity with an overlying sensory cutaneous nerve. Minimal sedation with oral (diazepam) or intravenous (midazolam and fentanyl) agents is recommended to provide adequate anxiolysis and analgesia. We have found in our practice that short-acting agents delivered intravenously offer better control, with quick recovery and better patient comfort, thus allowing fast-track postprocedure discharge from the facility or office. Midazolam IV (diazepam family) may offer some protection against lidocaine toxicity.

Catheter insertion: The catheter is inserted into the vein at its point nearest to the skin surface, usually just below or above the knee, using standard percutaneous (Seldinger) or cut-down technique. The catheter tip is positioned using ultrasound guidance approximately 2 cm distal to the saphenofemoral junction. This is critical to avoid thermal injury to the SFJ. All current Closure® devices (VNUS Medical Technologies, San Jose, CA) feature a central lumen that will accommodate either a 0.018 (ClosureRFST™) or 0.025 inch (ClosurePLUS™ and ClosureFAST™) diameter guide wire, to allow maneuverability through tortuous or difficult vein segments.

Limb anesthesia and vein compression: Once the catheter has been positioned safely below the SFJ, tumescent anesthesia can be introduced using a variety

of methods. It is important to use ultrasound visualization in order to insure that the fluid is placed beneath the saphenous fascia and above the deep muscular fascia and that it surrounds the vein completely, which serves to contain the radiant heat within the treated vein without significantly affecting adjacent cutaneous and sensory nerve tissues.¹⁵ The infusate also compresses the saphenous vein and its inflow branches in order to produce a “dry” vein. Contraction of the vein diameter is another benefit if diluted epinephrine is included in the tumescent anesthetic fluid. Tumescent anesthesia, using generous volumes of buffered lidocaine 1% with epinephrine 1:100,000 diluted to 0.1% placed properly, results in relatively pain-free status (*Table 1*). Care must be taken to avoid lidocaine toxicity - dosage guidelines are 7 mg/kg body weight, and no more than 500 mg should be used at one setting. Bilateral limb procedures may require an alternative anesthesia choice, such as general or regional (femoral nerve block, spinal, or epidural).

Ringer's lactate	500 cc
Withdraw 50 cc	-50 cc
	450 cc
Add lidocaine 1% with epinephrine 1:100,000	+50 cc
	500 cc
Add sodium bicarbonate (NaHCO ₃) 8.4%	+16 cc
Resultant solution is lidocaine 0.1% with epinephrine 1:1 million	516 cc

Table 1. Tumescent anesthesia solution preparation

Energy delivery: Prior to November 2007, during vein heating the patient was positioned in the Trendelenburg position, with approximately 15-20 degrees of angulation. More recently, as depicted in *Figure 2*, the patient's head and torso are kept in a relatively comfortable horizontal position while the limb to be treated is elevated at an angle of 30-45 degrees. Ultrasound imaging demonstrates that, while the patient remains comfortable, this extreme position allows for near complete emptying of the venous system with tight circumferential contact of the vein by the catheter. Gentle manual pressure with the DUS probe can be applied to the saphenofemoral junction area and then

along the course of the vein as necessary, while the catheter is withdrawn (ClosurePLUS™) or segmentally repositioned (ClosureFAST™).

Perioperative ultrasound: DUS should be used to document satisfactory closure of the treated vein just before removing the catheter from the vein. When ClosurePLUS™ is performed, a curious finding on ultrasound that may be observed is echogenic movement depicted in the occluded vein despite having obliterated the lumen. It probably represents movement of saline solution infused through the Closure® catheter in the vein and around the blood plug despite adequate obliteration of the lumen. If significant flow remains, the vein should be retreated. A word of CAUTION: when using the ClosureFAST™ catheter, NEVER re-advance the catheter to the SFJ, as doing so may dislodge fibrinous material cephalad into the proximal deep venous system. If concerned when treating very large diameter veins, approximately 10 mm or greater, one can simply double heat each 7 cm segment (two episodes, 20 seconds each) prior to repositioning the catheter. The transfer of heat with ClosureFAST™ is so uniform and efficient that the vein treated invariably closes when studied postoperatively with DUS.

Postoperative instructions: The patient is encouraged to ambulate immediately, returning in some cases to normal activities on the same day. Postoperative ultrasound imaging of the saphenofemoral junction

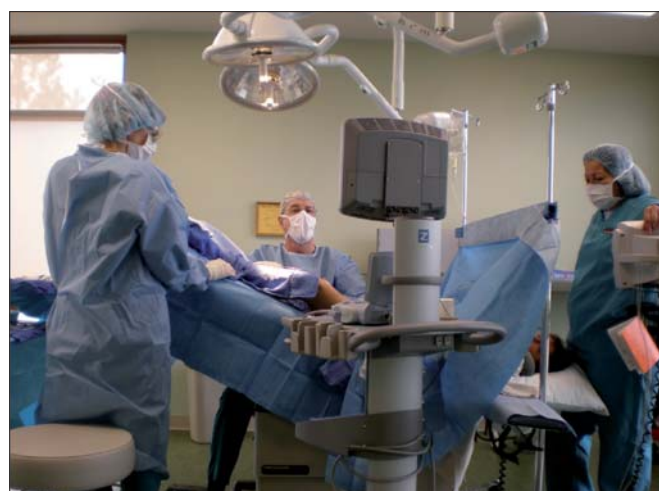

Figure 2. The tilt table in this treatment room allows the torso of the patient to be in a relatively supine position (patient's head can be seen to the right), while the leg to be treated is positioned with 30° or more of angulation.

within three days is an essential part of the protocol to check for successful obliteration and absence of clot extension into the common femoral vein. What is usually seen at this initial check is remarkably similar to an acute thrombosis of the vein with dilation and filling of the vein lumen with echo dense signals and failure to compress with externally applied pressure. This represents an element of thrombosis which aids the obliteration process.

MANAGEMENT OF COMPLICATIONS

Data collected for the VNUS Closure® Study Group Registry was prospective, looking for nerve injury, clot extension, hematoma, phlebitis, skin burns, and infection.¹⁶ Only limbs treated at 85°C and seen within the first postoperative week were included in the report, and only limbs treated with Closure® and ClosurePLUS™ catheters were included in the Registry. Results are shown in *Table II*. The most serious complication, although rare, is clot extension into the common femoral vein as it can lead to deep vein thrombosis (DVT) if not recognized and treated early with either low-molecular-weight heparin (LMWH) or operative thrombectomy. It is the practice at the Reno Vein Clinic to see all cases on

the first postoperative day and to include a postoperative duplex scan during that visit. If there is evidence of clot extending into the deep vein, then LMWH is prescribed at therapeutic doses for six days. Aspirin 325 mg is started on day 7 and continued for one month.

Nerve injury associated with RF ablation is seen as areas of hypoesthesia noted on follow-up examination in the first week postop. The majority of these occurred in the early Closure® cases before the routine instillation of tumescent anesthesia. To avoid nerve injury, following the early clinical experience, the Closure® procedure was recommended to be limited to above-knee GSV treatments.¹³ The greater saphenous nerve is actually adherent to the GSV in the distal leg and injury to this nerve is usually unavoidable when GSV RF ablation is attempted much below the knee.⁸

Skin burns, initially seen in a minority of early Closure® cases, essentially have vanished since the institution of tumescent anesthesia^{16,17} and the abandonment of the Eschmark leg wrap. The Eschmark rubber bandage has a tendency to roll back when applied to the funnel-shaped thigh, in which case it can act as a tight rubber band to push the skin closer to the saphenous vein. Ablation in

Complication	Follow-up interval	Rate of occurrence, % (n/N)
DVT (accompanied by pulmonary embolism in one instance)	One week	1.0 (3/286)
Skin burn – first half of study	One week	4.2 (6/143)
Skin burn – second half of study	One week	0 (0/143)
Infection	One week	0 (0/286)
Clinical phlebitis	One week	2.1 (6/286)
Clinical phlebitis	Six months	0.4 (1/223)
Paresthesia	One week	15.0 (43/286)
Paresthesia	Six months	9.4 (21/223)
Paresthesia	12 months	3.9 (9/232)
Paresthesia	24 months	5.6 (8/142)

Table II. Complications reported from the Closure Study Group

the thin or skinny leg should prompt careful attention to detail to minimize thermal injuries to the overlying skin due to excessive external compression, which can arise from the Eschmark bandage or the DUS probe during intraoperative monitoring.

Phlebitis can occur with the Closure® procedure as in any treatment of varicose veins, and it is usually the result of residual blood trapped within vein segments. Some degree of phlebitis is inherent in the whole process since the obliteration occurs as a result of injury to the vein by the heating process. It is occasionally seen as a tender, erythematous or ecchymotic band over the treated vein in the distal thigh. It resolves over several weeks without any specific treatment other than for symptomatic relief, eg, the use of nonsteroidal anti-inflammatory drugs, heat, and compression hosiery.

Patients may describe a curious sensation which occurs during the second or third postop week along the treated vein segment, usually in the distal thigh. They may experience a spontaneous or persistent dull feeling, or “bogginess”, or sharpness when stretching or extending the treated leg. This could represent an inflammatory process, which occurs as the body is healing the scald injury of the treated vein segment. The sensations usually abate over several weeks, consistent with the normal healing time of injured tissues.

EXPERIENCES AT THE RENO VEIN CLINIC

At the Reno Vein Clinic our routine practice is to conduct the first postoperative clinical and DUS examination at one day after RF obliteration, with periodic subsequent wellness visits as patient schedules permit. Following procedures performed from 1999 through March 2006 (using ClosurePLUS™ at 90°C since April 2002), we documented a total of 29 failures from 598 ClosurePLUS™ obliteration procedures having one-day postoperative DUS. All failures were detected at or prior to a three-year follow-up examination. There were 124 duplex examinations conducted beyond three years, 34 of which were five years or more following intervention, with no further failures observed. Only one case of DVT occurred related to aggressive heating near the SFJ. Since instituting routine use of tumescence, only two cases of second degree burns occurred, both on skinny male limbs; and temporary paresthesia rate of only a 2% was seen. Further details on our complications, which parallel the broader experience with the Closure®

procedure, were previously reported.¹⁸ In three cases in which SFJ reflux abolition was documented as successful one day postoperatively, reflux developed within three months (n=2) and nine months (n=1) through the SFJ and into pre-existing varicose veins via the anterolateral saphenous vein. Because of technical difficulties, significant thigh varicose veins had been left untreated at the time of the Closure® procedure. These three specific personal observations suggest that SFJ incompetence may be secondary to downstream venous insufficiency rather than a primary contributor to superficial venous insufficiency.

Other Saphenous Veins

From January 2002 to March 2006, RF ablation at the Reno Vein Clinic was extended to include several cases of anterior and posterior branches of the GSV in the proximal thigh. These results generally parallel those of the GSV. Also, during that period, 55 small (lesser) saphenous veins (SSVs) were successfully treated, with one instance of temporary sural nerve injury. All SSVs were confirmed closed at the one-day postoperative visit. When 90°C is used, successful short-term and mid-term outcomes appear to mimic those seen in the GSV group. In the case of SSV treatment, careful ultrasound guidance is critical for precise placement of the catheter electrodes to avoid inadvertent heating of the posterior tibial nerve. In our experience, pain located in the heel or foot at onset of heating indicates placement too close to the nerve. Tumescence infiltrated circumferentially around the SSV is a must to avoid injury to the sural nerve, which usually lies near the vein.

We have also begun extending the application of temperature-controlled RF vein obliteration to the treatment of incompetent perforators (up to 5 mm diameter) and 3-4 mm diameter short segment refluxing primary or tributary veins such as small saphenous, posterior and anterior saphenous veins. The rigid 2 mmX15 cm long ClosureRFS™ stylet can be introduced over a 0.018” guide wire and positioned under DUS guidance.

CLOSURE® TREATMENT RESULTS

Data on over 1000 limbs treated without high ligation have been collected in an ongoing Registry of the VNUS Closure® Treatment Study Group comprising 35 centers in the US, Europe, and Australia. Early results from this

registry at various follow-up periods through January 2002, as reported by Merchant et al, show successful ablation ranging from 93% at one week to 85% at two years, with absence of vein reflux (defined as absence of reversed flow at or near the SFJ or in any segment of the treated vein) of 90% at two years, and patient satisfaction of 95% at two-year follow-up. In addition, 111 of 142 limbs with 2-year DUS examinations were also scanned at 1 year; of these, only two (1.8%) changed from reflux-free at 1 year to DUS evidence of reflux at 2 years.¹⁶

In 2005, Merchant et al reported the 5-year Closure Study Group outcomes on 1222 vein segments treated at 85°C at 34 international centers, and included procedures performed during initial learning curve periods.¹⁹ Twelve of the 34 centers provided long-term follow-up. Reflux-free and vein occlusion rates in 117 limbs examined at five years were 83.8% and 87.2%, respectively. Clinical symptom improvement, measured by absence of limb pain, fatigue, or edema, was observed in 85% to 94% of limbs classified as having anatomic success at annual intervals over the 5-year period. Over the same interval, the 185 (15.1%) limbs presenting by DUS examination as anatomical failures exhibited 70% to 80% clinical improvement.

Several prospective randomized studies on the early results of Closure® treatment without high ligation compared with vein stripping and ligation have been published²⁰⁻²³ and show significant clinical superiority of the Closure® procedure. In a study from one center in Oulu, Finland,²⁰ significant advantages of the Closure® treatment were shown regarding less pain, early return to activities, fewer sick leaves from work, and better quality of life scores. When these findings included time lost from work, the authors found Closure® treatment to be cost effective despite initial high hospital costs. A three-year follow-up report demonstrated a durable ablation in all 15 RF-treated limbs.²⁴

Another study, EVOLVEs, supported by VNUS Medical Technologies, involved five centers in the US and Europe,²¹ and was designed to determine the early benefits of the procedure with follow-up limited to four months. Three-week results showed significant advantage of the Closure® procedure in that there was less pain, earlier return to activities and work, better quality of life scores, and better cosmetic results. When these patients were seen at the four-month follow-up,

these advantages had disappeared. Although the study was not designed to evaluate cost effectiveness, when the severity of infectious complications (which occurred only in the stripping and ligation group) were factored in, the authors ascribed a probable cost benefit to Closure®.

A one- and two-year follow-up of this multicenter study by Lurie et al¹² showed that 41% of obliterated GSVs became ultrasonically undetectable, and another 51% remained visible, but exhibited progressive diameter shrinkage. Vein remnants that remained visible by DUS were larger at the time of RF ablation than those that became invisible. Clinical status of limbs that underwent RF ablation was at least equal to the status of limbs that received vein stripping. The cumulative rate of recurrence of varicose veins was 14.3% in the RF group compared with 20.9% in the stripping group. Using the CEAP classification system, 33% of RF patients and 28% of stripping patients had no signs of venous disease at two years. Quality of life questionnaires were administered at all follow-up visits. While the observed superiority of the RF group over the stripping group diminished by four months, it re-emerged at both the one- and two-year intervals.

PERFORATING VEINS

Whiteley et al reported the first application of the ClosurePLUS™ catheter in treating incompetent perforating veins (IPVs) in 2003.²⁵ The procedure was performed on 770 IPVs in 506 limbs. At one year, 79% of IPVs were closed and had atrophied; 76% remained closed at 2 years. Encouraged by this early success, VNUS Medical Technologies designed Radiofrequency Stylet devices and implemented a standard protocol for the ablation of clinically significant IPVs. Peden and Lumsden, generally restricting the application to patients in the CEAP 4-6 categories and emphasizing the need to adequately treat the subfascial component of the IPV, described their technique for the treatment of IPVs and have reported early successes similar to those of Whiteley et al.²⁶

SAPHENOFEMORAL CONFLUENCE

Concern about the fate of the saphenofemoral confluence following elimination of the main trunk of the saphenous vein has been addressed by several reports.

Gradman, in a survey of members of the American Venous Forum and American College of Phlebology, concluded that regardless of the method of saphenous vein ablation (RF, laser, or foam sclerotherapy), concomitant ligation of the saphenofemoral junction offered no advantage in outcome no matter the size of the proximal great saphenous vein.²⁷ Boros et al, in a single community center retrospective analysis of outcomes of saphenous vein RF ablation, found no difference whether the junction was routinely, selectively, or never ligated: the DVT rate of 4% was equal across the board. The infection rate for SFJ ligation (5%) was limited to the groin incision and was significantly higher ($P=0.01$) than when no ligation was performed (0%).²⁸ In a retrospective study analyzing great saphenous vein stripping with subjunctional ligation (thus preserving the saphenofemoral confluence of tributaries), Pittaluga et al observed no reflux in the saphenofemoral confluence in 98.2% of cases with a mean follow-up of 24.4 months.²⁹ This finding is comparable to that of Pichot et al regarding analysis at 2 years following RF ablation without high ligation.¹¹

Regarding clinical usefulness of the RF ablation techniques, Frasier et al found successful treatment of selected Klippel-Trenaunay syndrome patients.³⁰ Vasquez et al reported successful venous stasis ulcer healing and the usefulness of the Venous Clinical Severity Score (VCSS) in assessing outcomes after saphenous vein RF ablation.³¹ Puggioni et al in a retrospective review of case studies at the Mayo Clinic concluded that postoperative complications, in their experience, were less frequent with RF ablation than with endovenous laser treatment (EVLT).³² (Author's note: these studies all utilized ClosurePLUS™ catheters.)

CLOSUREFAST™ — THE FUTURE

The endovenous Closure® procedure has evolved from the original catheter and techniques to the introduction of improved devices (ClosurePLUS™, ClosureFAST™) and techniques (tumescence) designed to improve outcomes and reduce the incidence of complications, and newly designed devices (ClosureRFS™) to broaden applications. The introduction of the ClosureFAST™ catheter in 2007 was intended to substantially shorten procedure time and it appears that it has done just that. The device has a 7 cm heating element that remains stationary during a 20-second energy delivery period. The catheter is then repeatedly retracted 6.5 cm and

energized for 20 seconds at each segment until the desired length of vein has been treated. The ClosureFAST™ catheter has undergone successful early clinical studies. Proebstle et al reported the first multicenter study of 252 GSVs treated in 194 patients. The average energy delivery time was 2.2 minutes over an average 36.7cm vein length; 16.4 minutes average elapsed time from catheter insertion to final removal. Initial vein occlusion was 100%, and life-table analysis out to 6 months indicated a 99.6% occlusion rate.³³ In follow-up, Proebstle reported a 96.7% occlusion rate for 223 vein segments at one year.³⁴

The Reno Vein Clinic began using ClosureFAST™ in May 2007, and by November 2007 had treated 138 saphenous vein segments of which 15 were SSV treatments. Within the first six months, only one segment had completely recanalized, and the complication rates were similar to those of the ClosurePLUS™ procedure. However, in several instances there were multiple interruptions of the procedure due to inadequate or uneven heating of the vein segments, which resulted in damage to the heating element portion of six ClosureFAST™ catheters. In November 2007, an adjustment was made in what proved to be a significant improvement to the technique — the limb undergoing treatment was elevated 30-45 degrees from the horizontal to effect complete emptying of the superficial venous system (*see Figure 2*). DUS demonstrated complete emptying of the saphenous vein with tumescence and elevation. Implementation of this maneuver resolved the uneven heating problem, and the average energy delivered to the vein segments dropped from 110 Joules/cm to 60 Joules/cm (average of two procedure measurements). From November 2007 to October 2008, 131 saphenous vein segments (of which 18 were SSVs) were treated with 100% initial occlusion and absence of hypoesthesia and deep venous thrombosis related to the RF procedure. Interruptions ceased and there were no further episodes of heat-related catheter damage. One patient suffered a second degree skin burn at the insertion site, probably as a result of inadvertent positioning of the catheter in the introducer sheath during the final segment treatment. Three key points of the ClosureFAST™ technique should be emphasized to assure a smooth and successful treatment of the patient:

1/ To avoid possible thermal injury to the SFJ, the catheter tip must be positioned 2 cm distal to the SFJ,

regardless of superficial epigastric vein location. One must reaffirm location by longitudinal and transverse DUS images.

- 2/ There is a step-up hub located 2 cm behind the heating element; use this indicator to locate the position of the catheter beneath the skin at the insertion site during the final segment treatment. This should help avoid skin burns at this location.
- 3/ Elevate the limb to be treated, either manually or by table reposition, 30-45 degrees during the short two- to four-minute treatment course. This provides complete emptying of the vein segment and allows a smooth, uninterrupted procedure.

CONCLUSIONS

The evidence published in peer-reviewed journals, four studies of which are level one, suggests that at least out to five years outcomes of RF obliteration of saphenous vein reflux are comparable to those of traditional stripping and ligation. The risks of serious complications such as DVT are low and comparable to those that attend stripping and ligation. Lesser complications, when they do occur, are time limited and usually of minor consequence.

Using the RF Closure® equipment and employing current techniques described in this report, an experienced clinician, modifying details to suit individual clinical settings, can expect the following: 1) 98% to 100% successful initial ablation; 2) less than 1% rate of complications such as common femoral vein clot extension and DVT, temporary sensory thermal nerve injury and second degree thermal skin injury; and 3) five-year ablation and reflux-free outcomes of >90%. In high-risk patients, eg, the obese, or those on anticoagulation or having comorbidities, the Closure® procedures may be the better treatment option because of the advantages they offer over traditional surgical methods, especially regarding less trauma. In cases where reflux originates distal to the saphenofemoral junction (which can only be appreciated by DUS), the Closure® method is ideally suited.

Neovascularization following this procedure at the saphenofemoral junction appears to occur rarely and

may not be a factor in later recurrent varicose veins, a possible distinct advantage in comparison with surgical stripping and high ligation.^{11,35} The persistent patency found in the superficial epigastric vein and other less frequently seen groin branches and the pattern of failures of the Closure® procedure have been described recently in the five-year report by the Closure® Study Group and the results are encouraging for long-term successful relief from superficial venous hypertension and reflux. There is little reason to doubt that results with the new ClosureFAST™ segmental heating catheter would be any different, if not better; short-term reports support this assertion.³⁴

Radiofrequency obliteration of saphenous vein reflux, with the caveat that it is done by a qualified physician, has become a safe, effective, and preferred alternative to traditional surgical techniques, evidenced by many publications including the Closure® Study Group five-year outcomes. Schmedt et al, reporting certain anatomical findings by an innovative research investigational tool, endoluminal optical coherence tomography, demonstrated a more uniform and complete disintegration of the radiofrequency (ClosurePLUS™, 6Fr)-treated bovine vein compared with endovenous laser-treated bovine vein.¹⁴ Whether radiofrequency deserves to be the treatment of choice among endovenous obliteration procedures will require further well-designed randomized studies. In the meantime it makes sense to offer this innovative technology as a primary choice for the patient with saphenous vein reflux of primary origin.

The author wishes to express his gratitude to Jeffrey S. Frisbie for his technical assistance in the preparation of this report.



Address for correspondence

Robert F. Merchant
The Reno Vein Clinic
9480 Double Diamond Pkwy, Ste. 100
Reno, NV, 89521
USA

E-mail: doc@renoveinclinic.com

REFERENCES

- Liu JK, Apfelbaum RI. Treatment of trigeminal neuralgia. *Neurosurg Clin N Amer.* 2004;15:319-334.
- Filingeri V, Gravante G, Cassisa D. Physics of radiofrequency in proctology. *Eur Rev Med Pharmacol Sci.* 2005;9:349-354.
- Brown DB. Concepts, considerations, and concerns on the cutting edge of radiofrequency ablation. *J Vasc Interv Radiol.* 2005;16:597-613.
- Gillams AR. The use of radiofrequency in cancer. *Br J Cancer.* 2005;92:1825-1829.
- Berjano EJ. Theoretical modeling for radiofrequency ablation: state-of-the-art and challenges for the future. *Biomed Eng Online.* 2006;April 18;5:24.
- Sadick N, Sorhaindo L. The radiofrequency frontier: a review of radiofrequency and combined radiofrequency pulsed-light technology in aesthetic medicine. *Facial Plast Surg.* 2005;21:131-138.
- Chandler JG, Pichot O, Sessa C, et al. Defining the role of extended saphenofemoral junction ligation: A prospective comparative study. *J Vasc Surg.* 2000;32:941-953.
- Chandler JG, Pichot O, Sessa C, et al. Treatment of primary venous insufficiency by endovenous saphenous vein obliteration. *Vasc Surg.* 2000;34:201-214.
- Nicolini P; Closure Group. Treatment of primary varicose veins by endovenous obliteration with the VNUS closure system: results of a prospective multicentre study. *Eur J Vasc Endovasc Surg.* 2005;29:433-439.
- Merchant RF, Pichot O, Myers KA. Four-year follow-up on endovascular radiofrequency obliteration of great saphenous reflux. *Dermatol Surg.* 2005;31:129-134.
- Pichot O, Kabnick LS, Creton D, et al. Duplex ultrasound scan findings two years after great saphenous vein radiofrequency endovenous obliteration. *J Vasc Surg.* 2004;39:189-195.
- Lurie F, Creton D, Eklof B, et al. Prospective randomised study of endovenous radiofrequency obliteration (closure) versus ligation and vein stripping (EVOLVeS): two-year follow-up. *Eur J Vasc Endovasc Surg.* 2005;29:67-73.
- Manfrini S, Gasbarro V, Danielsson G, et al. Endovenous management of saphenous vein reflux. *J Vasc Surg.* 2000;32:330-342.
- Schmedt CG, Meissner OA, Hunger K, et al. Evaluation of endovenous radiofrequency ablation and laser therapy with endoluminal optical coherence tomography in an ex vivo model. *J Vasc Surg.* 2007;45:1047-1058.
- Zikorus AW, Mirizzi MS. Evaluation of setpoint temperature and pullback speed on vein adventitial temperature during endovenous radiofrequency energy delivery in an in-vitro model. *Vasc Endovascular Surg.* 2004;38:167-174.
- Merchant RF, DePalma RG, Kabnick LS. Endovascular obliteration of saphenous reflux: A multicenter study. *J Vasc Surg.* 2002;35:1190-1196.
- Weiss RA, Weiss MA. Controlled radiofrequency endovenous occlusion using a unique radiofrequency catheter under duplex guidance to eliminate saphenous varicose vein reflux: A 2-year follow-up. *Dermatol Surg.* 2002;28:38-42.
- Merchant RF, Frisbie JS, Kistner RL. Endovenous radiofrequency obliteration of saphenous vein reflux. In: Pearce WH, Matsumura JS, Yao JS, eds. *Trends in Vascular Surgery 2006.* Evanston, IL: Greenwood Academic; 2007:429-442.
- Merchant RF, Pichot O; Closure study group. Long-term outcomes of endovenous radiofrequency obliteration of saphenous reflux as a treatment for superficial venous insufficiency. *J Vasc Surg.* 2005;42:502-509.
- Rautio T, Ohinmaa A, Perälä J, et al. Endovenous obliteration versus conventional stripping operation in the treatment of primary varicose veins: A randomized controlled trial with comparison of costs. *J Vasc Surg.* 2002;35:958-965.
- Lurie F, Creton D, Eklof B, et al. Prospective randomized study of endovenous radiofrequency obliteration (closure procedure) versus ligation and stripping in a selected patient population (EVOLVeS Study). *J Vasc Surg.* 2003;38:207-214.
- Stötter L, Schaaf I, Bockelbrink A. Comparative outcomes of radiofrequency endoluminal ablation, invagination stripping, and cryostripping in the treatment of great saphenous vein insufficiency. *Phlebology.* 2006;21:60-64.
- Hinchliffe RJ, Ubhi J, Beech A, Ellison J, Braithwaite BD. A prospective randomised controlled trial of VNUS closure versus surgery for the treatment of recurrent long saphenous varicose veins. *Eur J Vasc Endovasc Surg.* 2006;31:212-218.
- Perala J, Rautio T, Biancari F, et al. Radiofrequency endovenous obliteration versus stripping of the long saphenous vein in the management of primary varicose veins: 3-year outcome of a randomized study. *Ann Vasc Surg.* 2005;19:669-672.
- Whiteley MS, Price BA, Scott MJ, Gallagher TM. Radiofrequency ablation of refluxing great saphenous systems, Giacomini veins, and incompetent perforating veins using VNUS Closure and TRLOP technique. *Phlebology.* 2003;18:52.
- Peden E, Lumsden A. Radiofrequency ablation of incompetent perforator veins. *Perspect Vasc Surg Endovasc Ther.* 2007;19:73-77.
- Gradman WS. Adjunctive proximal vein ligation with endovenous obliteration of great saphenous vein reflux: does it have clinical value? *Ann Vasc Surg.* 2007;21:155-158.
- Boros MJ, O'Brien SP, McLaren JT, Collins JT. High ligation of the saphenofemoral junction in endovenous obliteration of varicose veins. *Vasc Endovascular Surg.* 2008;42:235-238.
- Pittaluga P, Chastanet S, Guex JJ. Great saphenous vein stripping with preservation of sapheno-femoral confluence: hemodynamic and clinical results. *J Vasc Surg.* 2008;47:1300-1304.
- Frasier K, Giangola G, Rosen R, Ginat DT. Endovascular radiofrequency ablation: a novel treatment of venous insufficiency in Klippel-Trenaunay patients. *J Vasc Surg.* 2008;47:1339-1345.
- Vasquez MA, Wang J, Mahathanaruk M, Buczkowski G, Sprehe E, Dosluoglu HH. The utility of the Venous Clinical Severity Score in 682 limbs treated by radiofrequency saphenous vein ablation. *J Vasc Surg.* 2007;45:1008-1014.
- Puggioni A, Kalra M, Carmo M, Mozes G, Gloviczki P. Endovenous laser therapy and radiofrequency ablation of the great saphenous vein: analysis of early efficacy and complications. *J Vasc Surg.* 2005;42:488-493.
- Proebstle TM, Vago B, Alm J, Göckeritz O, Lebard C, Pichot O. Treatment of the incompetent great saphenous vein by endovenous radiofrequency powered segmental thermal ablation: first clinical experience. *J Vasc Surg.* 2008;47:151-156.
- Proebstle TM, Vago B, Alm J, Göckeritz O, Lebard C, Pichot O. One year follow-up of radiofrequency segmental thermal ablation (RTFA) of great saphenous veins. Presented at American Venous Forum 20th annual meeting, February 20-23, 2008; Charleston, SC.
- Kianifard B, Holdstock JM, Whiteley MS. Radiofrequency ablation (VNUS closure) does not cause neo-vascularisation at the groin at one year: results of a case controlled study. *Surgeon.* 2006;4:71-74.



Nutcracker syndrome

Olivier HARTUNG

Service de Chirurgie Vasculaire, Centre Hospitalier Universitaire Nord, Marseille, France

The nutcracker syndrome is quite a rare condition. It is due to the compression of the distal segment of the left renal vein (LRV) between the superior mesenteric artery (SMA) and the aorta (also called left renal vein entrapment). El Sadr reported the first case in 1950,¹ but De Schepper named it.² This syndrome needs treatment when symptoms are disabling.

ANATOMY

The LRV arises from the left kidney and opens into the inferior vena cava after 5 to 9 cm (*Figure 1*). In its distal part, the LRV passes between the

anterior aspect of the juxtarenal aorta and the posterior aspect of the proximal segment of the superior mesenteric artery (SMA). The main tributaries of the LRV are the left gonadal vein, the left ureteral vein, capsular veins, lumbar veins, and the ascending lumbar vein from below and to the side, while the left middle suprarenal vein and the inferior phrenic vein come from above. There are also connections with the left hemiazygos vein and with internal and external vertebral plexuses.³ In rare cases (1.8%), the LRV can have a retroaortic course,⁴ or be doubled in a pre- and retroaortic course in a circumaortic LRV also known as renal collar (5.7%).⁴

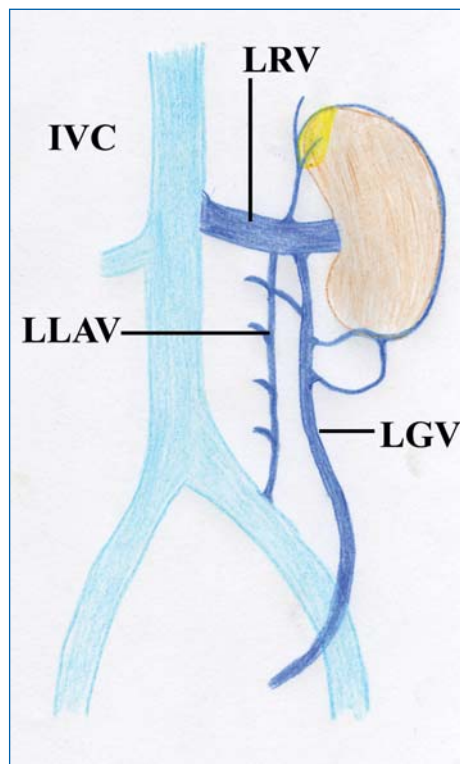


Figure 1: Anatomy of the left renal vein (LRV) and of its main tributaries (LGV: left gonadal vein, LLAV: left lumbar ascending vein).

Keywords:

Nutcracker syndrome, left renal vein, pelvic congestion syndrome, surgery, stenting

Phlebology. 2009;16(2):246-252.

The SMA normally originates from the aorta at a 90° angle with a ventral direction for 4-5 mm before taking a caudal direction. This short initial segment prevents LRV compression.

PATHOLOGY

Compression of the distal part of the LRV is generally due to the superior mesenteric artery arising from the aorta at an acute angle.^{5,6} Vein compression can also occur in patients with a retroaortic (posterior nutcracker syndrome) or a circumaortic LRV. Other factors have been reported as contributory or exclusive causes: posterior ptosis of the left kidney, abnormally high course of the LRV,⁷ and excessive fibrous tissue at the origin of the SMA.⁸

The compression induces venous obstruction of the LRV. This phenomenon leads to proximal venous pressure increase, which induces the development of varicose veins and collateral pathways.

CLINICAL PRESENTATION

Nutcracker syndrome occurs more frequently in women by the 3rd or 4th decades, although cases have been reported in children.^{9,10}

Symptoms can be due to venous hypertension within the left kidney: left-flank pain that can radiate to the buttock and hematuria (from microscopic to gross hematuria). Symptoms can also be the consequences of the development of collateral pathways:

- Pelvic congestion syndrome in women or varicocele in men due to massive reflux into the left gonadal vein. Pelvic congestion syndrome can include chronic pelvic pain, dyspareunia, dysmenorrhea, and urinary symptoms. Symptoms commonly worsen on standing or sitting and improve when lying down. It can also lead to the development of lower limb varicoses with superficial venous insufficiency, atypical varicose veins (buttock, posterior and the lateral aspect of the thigh...), or even recurrence after surgery for varicose veins.
- Myelitis and syringomyelia in very rare cases.¹¹ In addition, other symptoms as chronic pediatric fatigue syndrome¹² and gastrointestinal symptoms¹³

have been attributed to the nutcracker syndrome, but in these cases pathogenesis remains unclear.

IMAGING

Whatever the technique used, it should be remembered that LRV compression is increased by the standing position because of the weight of the bowel and thus may be underestimated in imaging examinations performed in decubitus (CT scan, magnetic resonance angiography, and phlebography). Fitoz¹⁰ showed that there were significant differences in LRV diameter at the aortomesenteric portion, diameter ratio, and SMA between the supine and upright positions.

Duplex scanning

Duplex scanning should be performed when the patient is in the fasting state and after 3 days of a no fiber diet. Horizontal, sagittal, and transverse sections should be used to examine the celiac region (*Figure 2*). Scanning should be used to search for LRV stenosis between the

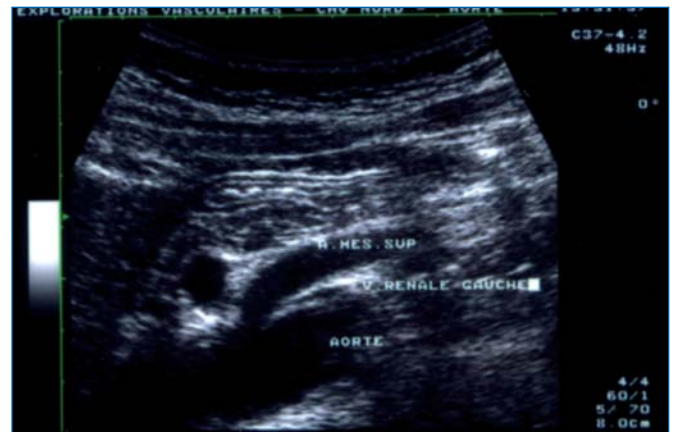

Figure 2: Duplex image of a transverse section in a patient with nutcracker syndrome.

superior mesenteric artery and the aorta, for flow abnormalities due to the obstruction, and for collateral pathways. The stenosis is evaluated by comparing the anteroposterior diameter of the LRV on the left side of the aorta and at the level of the stenosis.¹⁴ Flow should be analyzed by measurement of peak velocity at the stenosis and in the hilum of the left kidney.¹⁴ The main collateral pathway is the left gonadal vein and should be measured. Reversed caudal flow is often found. The SMA should also be analyzed: location of its origin, angle of the proximal segment, distance between the SMA and the aorta at the level of the LRV.

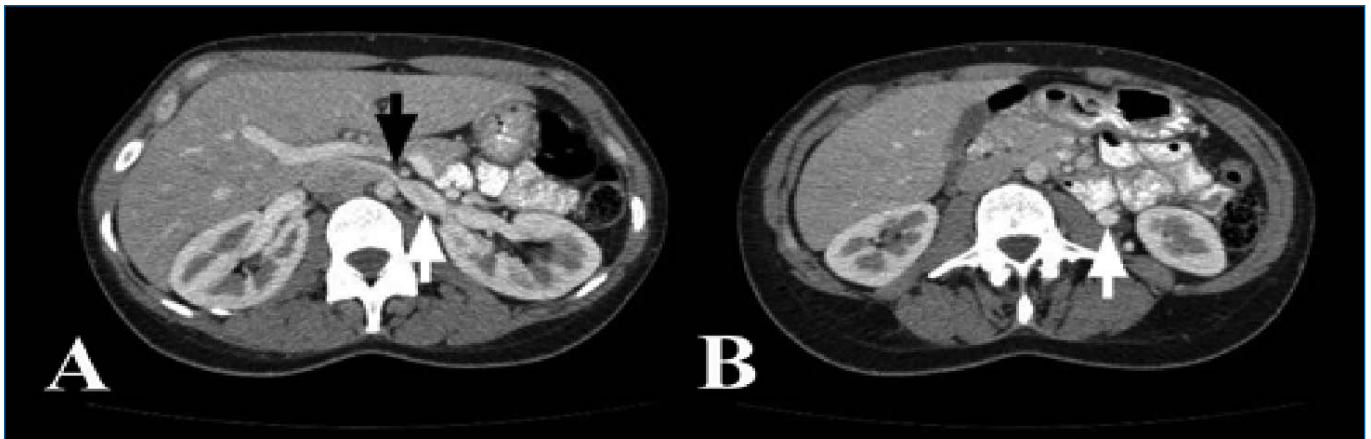


Figure 3: Computed tomography angiogram of a woman with nutcracker syndrome. A: Stenosis of the left renal vein between the superior mesenteric artery and the aorta (black arrow) with proximal dilatation of the left renal vein (white arrow). B: Dilatation and early opacification of the left ovarian vein (white arrow).

Kim¹⁴ suggested that a cut-off value of more than 5-fold for the ratio of the anteroposterior diameter and the ratio of peak velocity should be used as an ultrasound criterion in diagnosing the nutcracker syndrome.

The sensitivity and specificity of duplex scanning can be increased to 78% and 100%, respectively, by the addition to the diagnostic criteria of color flow in the collateral veins.¹⁵

Fitoz¹⁰ showed that upright position imaging revealed comparatively narrower SMA angles and more pronounced entrapment values in patients with nutcracker syndrome. The SMA angle measurement had sensitivity and specificity of 69.6% and 61.5%, respectively, in the supine position, and 87.0% and 76.9% in the upright position when the cutoff values were set to less than 41° and 21°, respectively.

Computed tomography angiography and magnetic resonance angiography

Both examinations offer multiplanar imaging and are noninvasive, and magnetic resonance angiography has the advantage of avoiding exposure to radiation. They should be performed before phlebography because they can exclude other causes of left flank pain and hematuria. These two examinations show the LRV and delineate its relation to the surrounding structures. They should be done during the portal phase to obtain the best opacification of the vein and to identify collateral pathways, which are opacified early.¹⁶

Left renal vein compression between the aorta and the superior mesenteric artery with proximal dilatation of

the vein is frequently found according to Buschi,¹⁷ 72% of whose patients had >50% stenosis. The compression is considered significant when the diameter of the proximal LRV is 5 times the diameter at the level of the stenosis. These examinations can also show varicose veins of the hilum of the left kidney and collateral pathways (*Figure 3*). Left ovarian vein reflux can be seen during the portal phase, when the infrarenal inferior vena cava is not yet opacified. The SMA frequently rises at an acute angle from the aorta, but can have a low or lateral origin, and the distance between the SMA and the aorta at the level of the LRV is reduced, as shown by Fu.¹⁸ In the case of posterior nutcracker syndrome, the vein follows a retroaortic course and is compressed between the aorta and the spine (*Figure 4*).

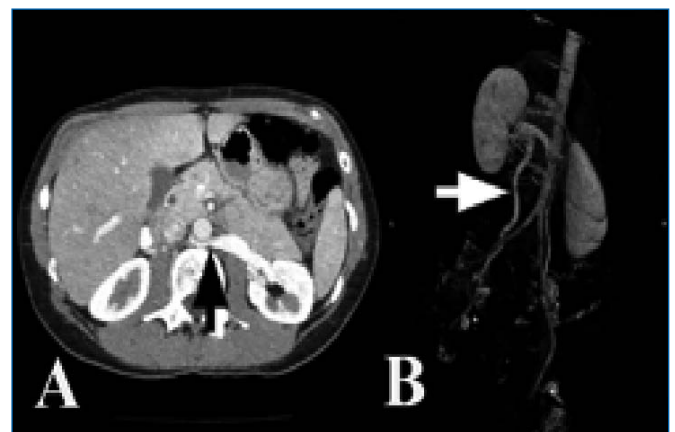


Figure 4: Posterior nutcracker syndrome A: Computed tomography angiogram showing the posterior location of the left renal vein with stenosis (black arrow) and proximal dilatation. B: Major reflux in the left ovarian vein (white arrow) with pelvic varices (posterior view)

Phlebography and pressure measurements

Selective LRV phlebography is performed under local anesthesia using a percutaneous approach with a femoral or brachial route. The compression of the LRV can be viewed and is associated with dye stasis. It can also reveal the presence of varicose veins or collateral pathways or both (Figure 5A). When left gonadal vein is refluxing, pelvic views should be obtained (Figure 5B). During this examination, the renocaval pullback gradient should be measured. It is <1 mm Hg in control patients.¹⁹ Nishimura regarded pressure gradients of 3 mm Hg or more as indicative of renal hypertension.²⁰ The value of this gradient can be discussed mainly in the case of major reflux in the left gonadal vein.

INVESTIGATIONS

Urological investigations

These are only used in cases of hematuria, which is commonly microscopic. At least 90% of red cells should be isomorphic on phase contrast microscopy if a glomerular cause of the hematuria is to be excluded. The urological work-up can include cystoscopy (localization of the hematuria to the left side) and flexible ureterorenoscopy or even renal biopsy.

Laboratory investigations

The coagulation profile should be normal and tests for urinary bilharziasis and tuberculosis should be negative.

TREATMENT

Only symptomatic and disabling nutcracker syndrome should be treated. Children should be treated

conservatively because cases of spontaneous remission have been reported during growth.^{21,22} Different approaches can be used.

Medical treatment

Medication can be proposed only in patients suffering from isolated pelvic congestion syndrome caused by nutcracker syndrome. In this case, symptoms can be improved by treatments effective in treating pelvic congestion syndrome, as medroxyprogesterone acetate (MPA, Provera, UpJohn Ltd, Kalamazoo, MI, USA),²³ goserelin acetate (AstraZeneca, Wilmington, DE 3.6 mg),²⁴ and micronized purified flavonoid fraction (Daflon 500 mg*, Servier, France, twice a day).²⁵

Surgical approach

Several techniques have been used to treat nutcracker syndrome and 56 cases have been reported in the literature.

Left renal vein transposition:

The LRV is approached and the left middle suprarenal vein is divided in order to allow LRV transposition.^{8,26-35} A clamp is applied to the IVC and the LRV is sectioned. A running suture is performed on the IVC. The LRV is reimplanted 3 to 5 cm below the formal opening. In case of associated pelvic congestion syndrome or varicocele, the left gonadal vein should be divided too. This technique can be performed by midline supraumbilical laparotomy, a right subcostal approach, or minilaparotomy. LRV transposition is nowadays regarded as the surgical method of choice,³⁴ and has been used to treat 28 patients, with excellent results in 27 cases and 1 recurrence.

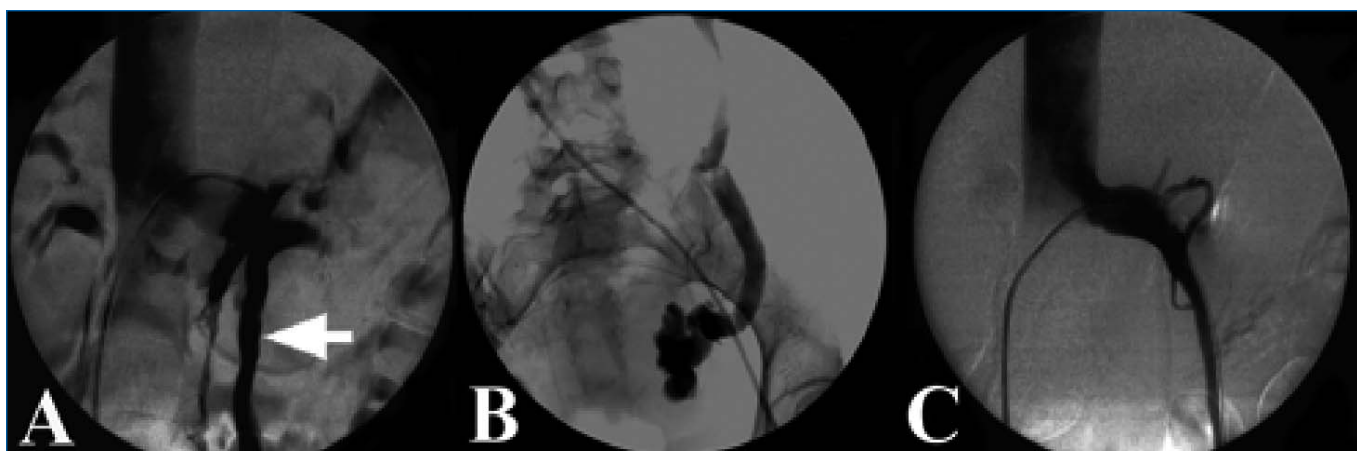


Figure 5: Angiogram of a patient with nutcracker syndrome.

A: Stenosis of the left renal vein, with dye stasis and collateral pathways (left gonadal vein, white arrow). B: Caudal view of the left ovarian vein with reflux and pelvic varicose. C: Result after stenting.

LRV bypass

A prosthetic or spiraled saphenous vein graft can be used in order to perform a bypass from the LRV to the IVC.³⁶

SMA transposition

The SMA is divided at its origin on the aorta and reimplanted under the LRV.^{8,37} This technique requires arterial clamping and reconstruction which can be performed within a short time, thus avoiding the risk of bowel ischemia. Its main risk is postoperative thrombosis.

Autotransplantation

This is an effective but highly invasive technique that exposes patients to the risks of renal ischemia and mainly of ureteral anastomosis.^{31,38}

Other techniques

External stenting,^{39,40} gonadocaval bypass,⁴⁰ left gonadal vein transposition,⁴¹ patch angioplasty,⁴² LRV phlebectomy,⁴³ renal fixation⁷ have also been reported. Hohenfellner even reported one case which was radically treated by nephrectomy.⁵

Endovascular approach

This approach is less invasive as it can be performed percutaneously.

Embolization

Under local anesthesia, a brachial or femoral percutaneous approach allows catheterization of the LRV and then of the gonadal vein, which is embolized using coils or a sclerosing agent or both.^{44,45} This percutaneous technique was used to improve symptoms in patients without renal symptoms (isolated varicocele or pelvic congestion syndrome). The main risk of this technique is the onset of renal symptoms as shown by Hartung,¹⁶ or even recurrence of pelvic congestion syndrome or varicocele as reported by Pallwein.⁴⁶ In fact, if the procedure is successful, the main collateral pathway is occluded, leading to worsening of LRV outflow and so to an increase in LRV pressure.

Balloon angioplasty

Only one case of balloon angioplasty has been reported, and the immediate results were good.⁴⁷

Stenting

Stenting¹⁶ should be performed under general anesthesia to avoid pain, and intravenous heparin should be given. The LRV is catheterized using a percutaneous femoral approach. A self-expanding stent (10 to 20 mm in diameter and 40 to 70 mm in length according to the literature) is deployed over a super-stiff guidewire and then dilated with a large balloon. Completion angiography is performed and the renocaval pullback gradient is measured before sheath removal (*Figure 5C*). Since the first case performed by Neste in 1996,⁴⁸ 34 cases have been reported,^{8,16,40,48-56} including 3 pediatric patients.⁵³ All patients were improved, but 3 had symptom recurrence. Moreover, 2 cases of early stent migration have been reported^{8,16} and 2 cases of late stent slipping.¹⁶ No restenosis has been reported, but none of these studies had a follow-up of more than 2 years.

CONCLUSION

The nutcracker syndrome is a rare condition, but is certainly underdiagnosed. It should be considered when patients present with left flank pain and hematuria, or pelvic congestion syndrome, or both. Duplex scanning and computed tomography angiography show the compression of the LRV, but diagnosis can be confirmed by selective phlebography. Endovascular treatment by stenting was proposed and is not very invasive, but follow-up is too short to establish the role of this technique in the management of the nutcracker syndrome. To date, surgery remains the gold standard.

* Daffon 500 mg (MPFF) is also registered under various trade names, including: Detralex, Arvenum 500, Elatec, Alvenor, Ardium, Capiven, Flebotropin, Variton, Venitol, Viatic

**Address for correspondence**

Olivier HARTUNG
Service de Chirurgie Vasculaire
CHU Nord
Chemin des Bourrelly
13915 Marseille Cedex 20
France

E-mail: olivier.hartung@ap-hm.fr

REFERENCES

1. El Sadr AR, Mina A. Anatomical and surgical aspects of the operative management of varicoceles. *Urol Cutan Rev.* 1950;54:257-262.
2. De Schepper A. Nutcracker phenomenon of the renal vein causing left renal vein pathology. *J Belg Rad.* 1972;55:507-511.
3. Satyapal KS. The renal veins: a review. *Eur J Anat.* 2003;7S1:43-52.
4. Satyapal KS, Kalideen JM, Haffejee AA, Singh B, Robbs JV. Left renal vein variations. *Surg Radiol Anat.* 1999;21:77-81.
5. Hohenfellner M, Steinbach F, Schultze-Lampel D, et al. The nutcracker syndrome: new aspects of pathophysiology, diagnosis and treatment. *J Urol.* 1991;146:685-688.
6. Shokeir AA, El-Diasty TA, Ghoniem MA. The nutcracker syndrome: new methods of diagnosis and treatment. *Br J Urol.* 1994;74:139-143.
7. Wendel RG, Crawford ED, Hehman KN. The nutcracker phenomenon: An unusual cause for renal varicosities with haematuria. *J Urol.* 1980;123:761.
8. Zhang H, Li M, Jin W, San P, Xu P, Pan S. The left renal entrapment syndrome: diagnosis and treatment. *Ann Vasc Surg.* 2007;21:198-203.
9. Shin JI, Park JM, Lee JS, Kim MJ. Effect of renal Doppler ultrasound on the detection of nutcracker syndrome in children with hematuria. *Eur J Pediatr.* 2007;166:399-404.
10. Fitoz S, Ekim M, Ozcakar ZB, Elhan AH, Yalcinkaya F. Nutcracker syndrome in children. *J Ultrasound Med.* 2007;26:573-580.
11. Frantz P, Jardin A, Aboulker J, Küss R. Responsibility of the left renal vein and inferior vena cava in certain cases of myelitis and syringomyelia. Value of ligation of the venous reno-spinal trunk. A propos of 30 cases. *Ann Urol.* 1986;20:137-141.
12. Takahashi Y, Ohta S, Sano A, et al. Does severe nutcracker phenomenon cause pediatric fatigue? *Clin Nephrol.* 2000;53:174-181.
13. Hilgard P, Oberholzer K, Meyer zum Büschenfelde KH, Hohenfellner R, Gerken G. Das "Nußknacker-Syndrom" der Vena renalis (Arteria-mesenterica-superior-Syndrom) als Ursache gastrointestinaler Beschwerden. *Dtsch Med Wschr.* 1998;123:936-940.
14. Kim SH, Cho SW, Kim HD, Chung JW, Park JH, Han MC. Nutcracker syndrome: diagnosis with Doppler US. *Radiology.* 1996;198:93-97.
15. Takebayashi S, Ueki T, Ikeda N, Fujikawa A. Diagnosis of the nutcracker syndrome with color Doppler sonography: correlation with flow patterns on retrograde left renal venography. *Am J Roentgenol.* 1999;172:39-43.
16. Hartung O, Grisoli D, Boufi M, et al. Endovascular stenting in the treatment of pelvic vein congestion caused by nutcracker syndrome: lessons learned from the first five cases. *J Vasc Surg.* 2005;42:275-280.
17. Buschi AJ, Harrison RB, Norman A, et al. Distended left renal vein: CT/sonographic normal variant. *Am J Roentgenol.* 1980;135:339-342.
18. Fu W, Hong B, Xiao Y, et al. Diagnosis of the nutcracker phenomenon by multislice helical computed tomography angiography. *Chinese Med J.* 2004;117:1873-1875.
19. Beinart C, Sniderman KW, Tamura S, Vaughan ED, Sos TA. Left renal vein to inferior vena cava pressure relationship in humans. *J Urol.* 1982;127:1070-1071.
20. Nishimura Y, Fushiki M, Yoshida M, et al. Left renal vein hypertension in patients with left renal bleeding of unknown origin. *Radiology.* 1986;160:663-667.
21. Tanaka H, Waga S. Spontaneous remission of persistent severe haematuria in an adolescent with nutcracker syndrome: Seven years' observation. *Clin Exp Nephrol.* 2004;8:68-70.
22. Shin JI, Park JM, Lee SM, et al. Factors affecting spontaneous resolution of hematuria in childhood nutcracker syndrome. *Pediatr Nephrol.* 2005;20:609-613.
23. Faquhar CM, Rogers V, Franks S, Pearce S, Waldsworth J, Beard RW. A randomized controlled trial of medroxyprogesterone acetate and psychotherapy for the treatment of pelvic congestion. *Br J Obstet Gynaecol.* 1989;96:1153-1162.
24. Soysal ME, Soysal S, Vicdan K, Ozer S. A randomized controlled trial of goserelin and medroxyprogesterone acetate in the treatment of pelvic congestion. *Hum Reprod.* 2001;16:931-939.
25. Simsek M, Burak F, Taskin O. Effects of micronized purified flavonoid fraction (Daflon) on pelvic pain in women with laparoscopically diagnosed pelvic congestion syndrome: a randomized crossover trial. *Clin Exp Obstet Gynecol.* 2007;34:96-98.
26. Stewart BH, Reiman G. Left renal venous hypertension "nutcracker" syndrome. Managed by direct renocaval reimplantation. *Urology.* 1982;20:365-369.
27. Ariyoshi A, Nagase K. Renal hematuria caused by "nutcracker" phenomenon: a more logical surgical management. *Urology.* 1990;35:168-170.
28. Ishidoya S, Chiba Y, Sakai K, Orikasa S. Nutcracker phenomenon: a case with surgical treatment and its diagnostic criteria. *Hinyokika Kyo.* 1994;40:135-138.
29. Ohki T, Miyahara M, Nakajima Y, Matsumoto K. Nutcracker phenomenon treated with left renal vein transposition: a case report. *Hinyokika Kyo.* 1999;45:183-186.
30. Hohenfellner M, D'Elia G, Hampel C, Dahms S, Thuroff JW. Transposition of the left renal vein for treatment of the nutcracker phenomenon: long-term follow-up. *Urology.* 2002;59:354-357.
31. Ali-El-Dein B, Osman Y, Shehab El-Din AB, El-Diasty T, Mansour O, Ghoneim MA. Anterior and posterior nutcracker syndrome: a report on 11 cases. *Transplant Proc.* 2003;35:851-853.
32. Kim JY, Joh JH, Choi HY, Do YS, Shin SW, Kim DI. Transposition of the left renal vein in nutcracker syndrome. *Eur J Vasc Endovasc Surg.* 2006;31:80-82.
33. Rudloff U, Holmes RJ, Prem JT, Faust GR, Moldwin R, Siegel D. Mesoaoartic compression of the left renal vein (nutcracker syndrome): case reports and review of the literature. *Ann Vasc Surg.* 2006;20:120-129.
34. Gloviczki P, Kalra M, Duncan AA, B, et al. Nutcracker syndrome: left renal vein transposition. The first line treatment. In: Becquemini JB, Alimi YS, Gerard JL, eds. *Controversies and updates in vascular surgery.* Torino, Italy: Edizioni Minerva Medica; 2008:360-366.
35. Hartung O, Benmiloud F, Barthelemy P, Dubuc M, Boufi M, Alimi YS. Late results of surgical venous thrombectomy with ilio caval stenting. *J Vasc Surg.* 2008;47:381-387.
36. Shaper KR, Jackson JE, Williams G. The nutcracker syndrome: an uncommon cause of haematuria. *Br J Urol.* 1994;74:144-146.
37. Thompson PN, Darling RC 3rd, Chang BB, Shah DM, Leather RP. A case of nutcracker syndrome: treatment by mesoaoartic transposition. *J Vasc Surg.* 1992;16:663-665.

REFERENCES

38. Chuang CK, Chu SH, Lai PC. The nutcracker syndrome managed by autotransplantation. *J Urol.* 1997;157:1833-1834.
39. Barnes RW, Fleisher HL 3rd, Redman JF, Smith JW, Harshfield DL, Ferris EJ. Mesoaortic compression of the left renal vein (the so-called nutcracker syndrome): repair by a new stenting procedure. *J Vasc Surg.* 1988;8:415-421.
40. Scultetus AH, Villavicencio JL, Gillespie DL. The nutcracker syndrome: its role in the pelvic venous disorders. *J Vasc Surg.* 2001;34:812-819.
41. Hartung O, Barthelemy P, Berdah SV, Alimi YS. Laparoscopy-assisted left ovarian vein transposition to treat one case of posterior nutcracker syndrome. *Ann Vasc Surg.* In press.
42. Andrianne R, Limet R, Waltregny D, de Leval J. Haematuria caused by nutcracker syndrome: Post operative confirmation of its presence. *Prog Urol.* 2002;12:1323-1326.
43. Pastershank SP. Left renal vein obstruction by a superior mesenteric artery. *J Canad Ass Rad.* 1974;25:52-54.
44. d'Archambeau O, Maes M, De Schepper AM. The pelvic congestion syndrome: role of the "nutcracker phenomenon" and results of endovascular treatment. *JBR-BTR.* 2004;87:1-8.
45. Rudloff U, Holmes RJ, Prem JT, Faust GR, Moldwin R, Siegel D. Mesoaortic compression of the left renal vein (nutcracker syndrome): case reports and review of the literature. *Ann Vasc Surg.* 2006;20:120-129.
46. Pallwein L, Pinggera G, Schuster AH, et al. The influence of left renal vein entrapment on outcome after surgical varicocele repair: a color Doppler sonographic demonstration. *J Ultrasound Med.* 2004;23:595-601.
47. Takahashi Y, Sano A, Matsuo M. An effective "transluminal balloon angioplasty" therapy for pediatric chronic fatigue syndrome with nutcracker phenomenon. *Clin Nephrol.* 2000;53: 77-78.
48. Neste MG, Narasimham DL, Belcher KK. Endovascular stent placement as a treatment for renal venous hypertension. *J Vasc Interv Radiol.* 1996;7:859-861.
49. Segawa N, Azuma H, Iwamoto Y, et al. Expandable metallic stent placement for nutcracker phenomenon. *Urology.* 1999;53:631-633.
50. Park YB, Lim SH, Ahn JH, et al. Nutcracker syndrome: intravascular stenting approach. *Nephrol Dial Transplant.* 2000;15:99-101.
51. Chiesa R, Anzuini A, Marone EM, et al. Endovascular stenting for the nutcracker phenomenon. *J Endovasc Therapy.* 2001;8:652-655.
52. van der Laan L, Vos JA, de Boer E, van den Berg JC, Moll FL. The central-venous compression syndrome: rare, but adequately treatable with endovascular stenting. *Ned Tijdschr Geneesk.* 2004;148:433-437.
53. Chen W, Chu J, Yang J, et al. Endovascular stent placement for the treatment of nutcracker phenomenon in three pediatric patients. *J Vasc Interv Radiol.* 2005;16:1529-1533.
54. Kim SJ, Kim CW, Kim S, et al. Long-term follow-up after endovascular stent placement for treatment of nutcracker syndrome. *J Vasc Interv Radiol.* 2005;16:428-431.
55. Basile A, Tsetis D, Calcara G, Figuera M, Patti MT, Ettorre GC. Percutaneous nitinol stent implantation in the treatment of nutcracker syndrome in young adults. *JVIR.* 2007;18:1042-1046.
56. Wei SM, Chen ZD, Zhou M. Intravenous stent placement for treatment of the nutcracker syndrome. *J Urol.* 2003;170:1934-1935.



Shave therapy for venous ulcers— a review and current results

Hans Joachim HERMANNNS
Peter WALDHAUSEN

*Clinic for Vascular Medicine,
Venous and Wound Care Center, Krefeld,
Germany*

SUMMARY

Shave therapy was established by Schmeller, mostly in Europe, and is not common in the international literature. The technique involves layered tangential and only suprafascial necrosectomy and fibrosectomy of nonhealing venous leg ulcers, combined with simultaneous skin grafting. In spite of very good long-term results confirmed by several investigators and published as a retrospective analysis, there are no prospective and randomized studies. Long-term healing rates between 70% and 80% for recalcitrant venous leg ulcers are very good, and no other current method is able to achieve comparable results. Further advantages are a simple technique, short intervention, and safety, with few complications. On account of the low risks, shave therapy is especially suitable for older patients with nonhealing leg ulcers. But one reason for the good results is a standardized postinterventional treatment regimen, including lifelong compression therapy (stockings), patient training and information on how to manage their disease, regular follow-up of wound healing, and inclusion of ambulatory care services.

INTRODUCTION

A large number of treatment options for venous leg ulcers have emerged over the years, and no other specific disease is characterized by a larger polypragmasy. Nonetheless, most ulcers will be healed by conservative methods, especially compression therapy. However, it is estimated that approximately 25% of all lesions have to be characterized as nonhealing. According to the results of the Bonn Vein Study (2004), the current epidemiological study of venous diseases in Germany, 0.1% (100 000 patients) suffer from acute venous ulcers (C6 according to CEAP classification). This gives a figure of about 25 000 patients with nonhealing leg ulcers. The German Society of Phlebology guidelines define nonhealing or recalcitrant as no tendency to heal with conservative treatments after 3 months or no healing after one year (*Figure 1*).

Keywords:

venous leg ulcer, postthrombotic syndrome, shave therapy, fasciectomy

Surgical procedures should be considered for patients with nonhealing ulcers. Conservative treatment alone seems to be insufficient and unsuccessful. The following options are available:

- venous surgery or endovenous procedures

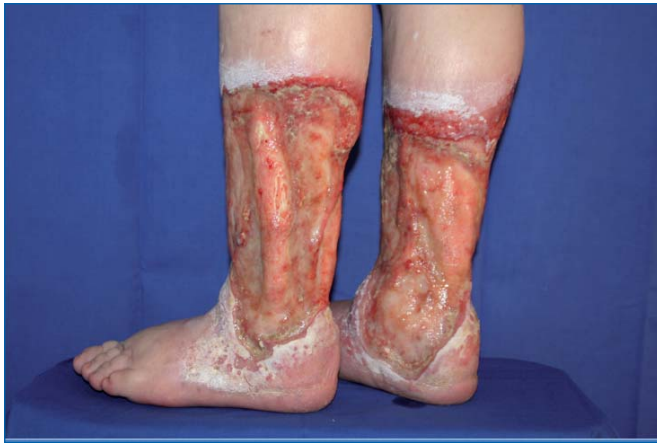

Figure 1: Severe recalcitrant venous leg ulcers – duration 42 years

- operative techniques involving the fascia cruris (paratibial fasciotomy and fasciectomy) and
- local ulcer surgery (shave therapy, Homan excision)

Shave therapy, which is described below, has come to play a major role, particularly in some European countries (Germany, Austria, Switzerland, France).

HISTORY AND DEVELOPMENT

As early as 1956, Hynes recognized that an adequate capillary plexus of the wound bed was necessary for successful free skin grafting. He was the first to apply shave therapy in the context of plastic surgical interventions, often in cases of chronic radiation dermatitis.¹ Quaba, also a plastic surgeon, was the first to employ “layered shaving” in cases of recalcitrant leg ulcers and, in 1987, he reported the successful treatment of 32 patients (58 ulcers). He recognized early on that the presence of granulation tissue was insufficient for a transplant and that shave therapy allowed the formation of a fresh wound with good conditions for graft healing. The results were independent of the clinical extent of the lesions and the bacteriological status.²

The German dermatologist and phlebologist Schmeller adopted and applied these findings and practical experiences, and established the procedure through various scientific publications, especially in the years from 1994 to 1999. But shave therapy is not well known in international phlebology and is not established in the world as a good choice or standard in the treatment of recalcitrant venous leg ulcers.³ Reasons are a lack of international studies, publications, and papers at

international meetings. There is a great need to compare studies under same conditions (etiology, ulcer size and duration, long-term results, quality of life).

ETIOLOGY

The origin of the chronic venous insufficiency is crucial for the long-term prognosis after operative procedures. If the ulcers are caused by primary superficial incompetence without deep venous involvement, they usually have long-term healing potential after removal of the insufficient venous segments by surgery or endovenous procedure. In very large ulcers, whose spontaneous healing is uncertain, simultaneous shave therapy with mesh graft shortens the healing process. If a leg ulcer is caused by deep venous insufficiency, the prognosis is poorer. In such cases, an earlier recurrence of the ulcer is to be expected. The worst long-term prognosis is seen in ulcers based on postthrombotic syndrome. Special types, such as capillaritis alba, mixed ulcers, and ulcers based on vasculitis also present a large therapeutic problem.

TECHNIQUE

Using a hand dermatome (Quaba, Schmeller, Bechara) or a skin graft machine (Hermanns), layered tangential and exclusively suprafascial necrosectomy and fibrosectomy of the ulcerations are performed until rich capillary bleeding is seen at the base of the wound.^{1,3,4} It is recommended to use an electro-dermatome (Aesculap® Accu Dermatome) or a dermatome with drive shaft, which allows an even more exact shave and a more comfortable procedure. A layer thickness of

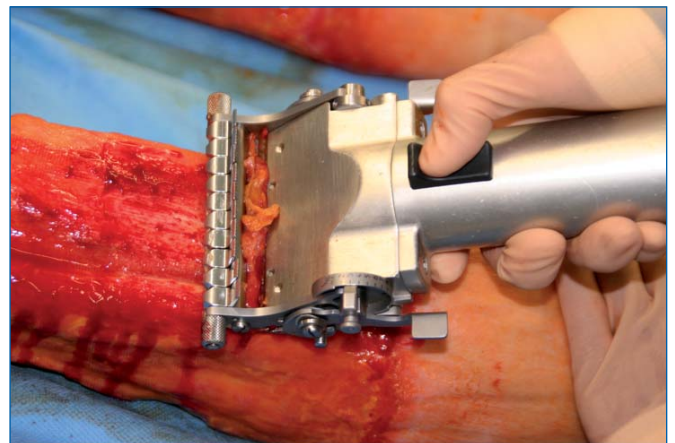


Figure 2: Shave therapy – tangential suprafascial necrosectomy and fibrosectomy of ulcer lesions

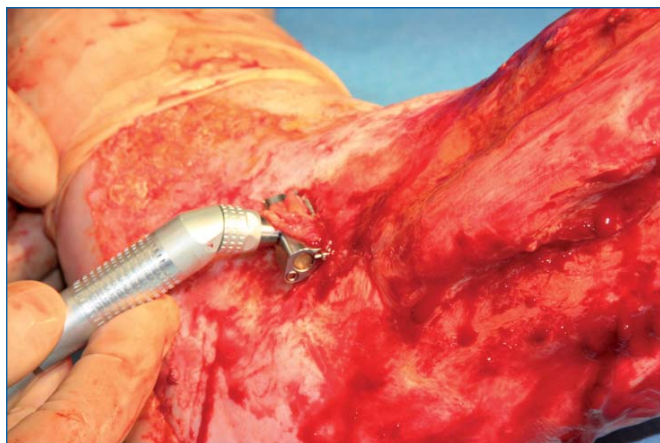


Figure 3: Small shaver for difficult areas

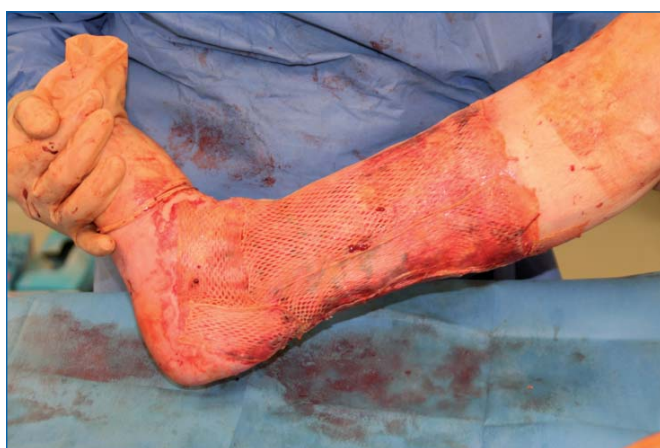

Figure 4: Simultaneous meshgraft

between 0.3 and 0.4 mm is recommended, in order to avoid reaching the deep tissue layers too quickly which could incur the risk of structural injury (capsule ligaments of the joints, Achilles tendon).

The skin graft is usually taken from the affected leg. Here also, a thickness of 0.3 to 0.4 mm is favorable. The ratio of mesh should be around 1:1.5, if enough skin is available. A thicker mesh skin leads to poorer healing rates, a larger mesh ratio reduces the ability to bear everyday strain (Figures 2, 3, 4).

CURRENT RESULTS FROM THE KREFELD VENOUS AND WOUND CARE CENTER

Patients and Methods

The data reported below are from a retrospective analysis of the results of 451 shave treatments, performed on 363

affected legs (278 patients), between 1.1.1998 and 3.31.2007, at the Krefeld Venous and Wound Care Center.

Before surgery, a complete work-up was done for all patients, including noninvasive examination of the venous and arterial vascular system, especially using duplex sonography as an imaging procedure. Invasive procedures, such as ascending phlebography, angiography, and magnetic resonance imaging, are available for investigating specific questions. The measurement of compartment pressure as well as morphologic examination of the calf using magnetic resonance imaging, enhances the diagnostic repertoire. The clinical course of therapeutic resistance is vital for the indication for operative intervention. Collection of 88 data points per patient was carried out using a special documentary sheet, which included:

- vascular status
- local ulcer documentation
- specific medical history
- comorbidities
- treatment performed
- discharge report
- questioning of patient regarding pain and general well-being during hospitalization

Based on the visual analog scale, the level of pain and general well-being was noted before the operation and at the time of the first change of bandage on the fourth postoperative day. All ulcers were measured and photodocumented before the operation (planimetry). Follow-up examinations were at 2, 4, and 16 weeks, and annually thereafter at a fixed time. Photodocumentation was always performed.

The mean duration of an ulcer before surgery was 16.4 years (0.4–62 years). Using planimetry, median ulcer size was ascertained to be 127 cm² (5–720 cm²) before treatment.

Results

At the time of follow-up in March 2007:

- 289 legs had completely healed (79.6%)
- 30 legs (8.2%) had residual lesions whose surface area on discharge from hospital was less than 10% of the initial ulcer surface area. These lesions continued to show a good tendency to heal
- 44 legs (12.2%) had to be categorized as failure

The median duration of the follow-up is currently about 57.4 months. Comparison with follow-up data in 12/2000 (77.5%), 6/2001 (81.0%), 3/2002 (88.0%), 3/2003 (82.0%), and 3/2004 (80%) shows that stable healing rates can be maintained (Table I, Figure 5).

If the data are presented as a cumulative healing rate on the basis of life table analysis, the results and prognosis are equally good and healing conditions are stable over a long period (Figure 6).

Results and etiology

If the etiology of the ulcers is included in the analysis of the results, 17 legs (4.8%) had recalcitrant leg ulcers caused by primary venous insufficiency. Removal of insufficient venous segments by crosssection and

stripping with simultaneous shave therapy was carried out in these cases. All ulcers of this group had healed at the time of last follow-up. 346 legs (95.2%) had pathological changes in the deep venous system in the sense of a postthrombotic syndrome or deep venous insufficiency of other origin. At the end, most of the recurrences were seen in this patient group.

Shave therapy and pain

The intensity of pain caused by the ulcer was evaluated preoperatively with an average score of 6.8 on a scale of 0 to 10 points. Postoperatively, at the first change of dressing, nearly all patients reported no pain (0.8 points). Pain reduction is an important factor in the physiological and psychological healing process.

	12/2000	6/2001	2/2002	3/2003	3/2004	3/2005	3/2006	3/2007
Patients (N)	60	74	88	111	151	193	244	278
Legs (N)	71	88	105	140	189	249	320	363
Shave therapy	104	120	149	207	270	335	382	451
Mean duration	15.1	15.3	16.1	16.3	16.0	16.3	16.6	16.4
Complete healing	77.5%	81.0%	88.0%	82.0%	80.0%	79.2%	77.5%	79.6%
Residual lesion	14.0%	9.0%	6.5%	10.0%	12.6%	8.4%	9.7%	8.2%
Failure	8.5%	10.0%	5.5%	8.0%	7.4%	12.4%	12.8%	12.2%
Follow-up	9.5	13.5	18.5	26.6	34.0	43.3	51.5	57.4

Table I: Shave therapy of nonhealing venous leg ulcers: long-term results

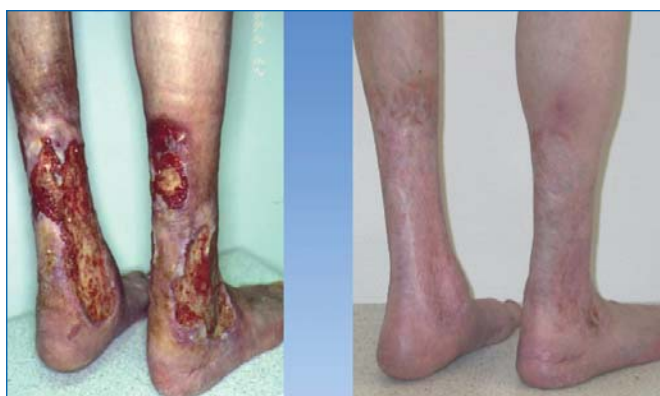

Figure 5: Long-term result after shave therapy (1999-2007)

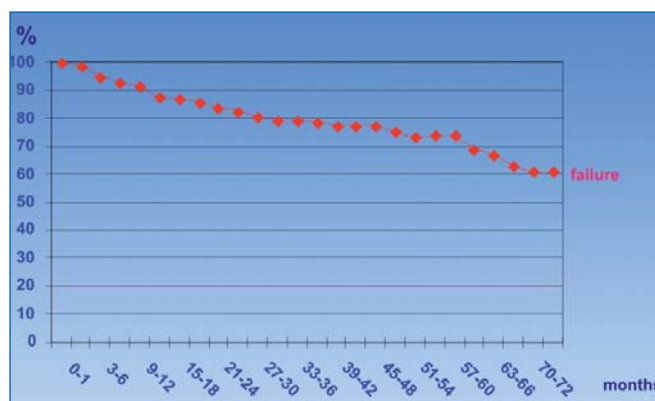


Figure 6: Shave therapy - cumulative healing rate

Complications

Generally shave therapy is a very safe procedure and complications are rare.

After 451 interventions, we found the following complications:

- 2 septic fever
- 4 erysipelas
- 1 lymphatic fistula
- 1 pneumonia
- 1 necrotizing fasciitis

In the case of a patient with long-term drug addiction, fulminant necrotizing fasciitis was seen in the third postoperative week. This led to the patient's death in the context of recurring deep vein thrombosis with pulmonary embolism. But this complication is not to be interpreted as specific to the intervention.

Shave therapy and the older patient

76% of the patients were older than 60 years at the time of operation, and 21% were aged between 80 and 99. A total of 11 patients older than 90 survived the intervention without complications. The results in the older patients at follow-up were as good as in the younger group (ulcer healing rate 80%). Even the patients who died had a high healing rate (84.5%) until their death. Pain and wound care were clearly reduced. On account of the low risks, shave therapy is suitable for older patients with nonhealing leg ulcers (*Figure 7*).

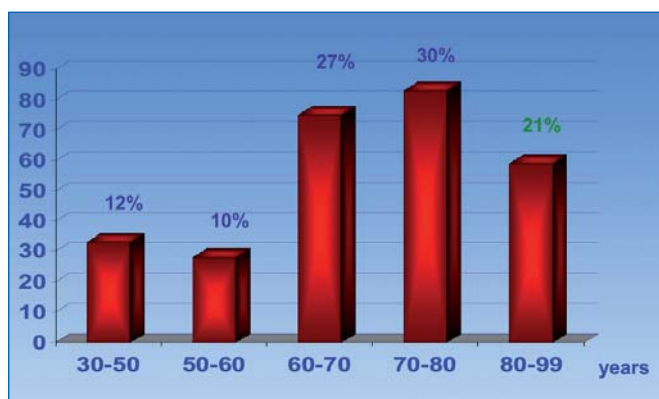


Figure 7: Shave therapy and age

CONCLUSION

Long-term results after shave therapy are very good, with a complete healing rate of 79.6%. In Germany, shave therapy is the first-choice operative treatment in

recalcitrant venous leg ulcers. Schmeller, Popescu, Obermayer, and other authors have achieved comparable healing rates (70%-80%) after surgery.³⁻⁶

Local and general postoperative side effects are rare, as is injury of deep tissue structures (eg, Achilles tendon with widespread dermatolipofasciosclerosis). The use of skin graft machines guarantees a short operative procedure, which, depending on the size of the lesions, usually lasts less than 30 minutes.

The technique is simple and easy to learn. Compared with crural fasciectomy, trauma is noticeably reduced through the exclusive suprafascial procedure. As a result, hospitalization is shorter (mean of 34 days for all patients) than for patients following crural fasciectomy, for which hospital stays of 50 days have been reported.

Our investigations relating to the pain experienced in cases of venous leg ulcers were surprising. With 6.8 on the 10-point visual analog scale, patients suffer more than we generally assumed. Extensive necrosectomy rapidly reduces pain. Despite the new and sometimes large wound surfaces, patients are generally free of symptoms from the first postoperative day. On average, leg ulcers had been present for 16.4 years before operation. After creation of a fresh wound, skin-graft healing can ensue, even after a latency period of up to 40 years.

Good long-term results can only be assured by standardized accompanying treatment. Compression therapy—if possible with a compression stocking—should be lifelong. Avoidance of edema through application of intermittent compression therapy at home is an important point of the treatment concept. Patient training and information on how to deal with the disease and on the care of skin and transplants motivates patients and results in a high level of compliance.

In the early stages of hospitalization, patients get practice by the attending physicians on how to change their dressings daily, how to apply their bandages and take care for their skin. They also learn to wear their compression stockings correctly. In order to guarantee long-term success, it is also important to involve and educate ambulatory care services, especially for the care of elderly patients. These healthcare services are requested to take part in a joint visitation and discussion prior to the discharge of the patient.

Shave therapy—standard of care?

It is quite difficult to recommend shave therapy as a standard technique for healing recalcitrant leg ulcers, because it is only established in certain parts of Europe. So far there is an obvious lack of international recognition and experience. Evidence-based state-of-the-art treatment today is characterized by wound preparation through an effective granulation tissue supported by vacuum-assisted closure therapy and autologous skin grafting as a second step.⁷ Ulcer shaving on the other hand removes necrotic tissue, fibrosis and granulation tissue and creates fresh wound leading to conditions of primary wound healing. Simultaneous skin grafting (mesh graft) is indispensable. Further studies are needed to confirm the importance of shave therapy in the treatment of venous leg ulcers. It is simple and the operation is generally short and safe.

Mostly in Europe shave therapy, as a “local ulcer surgery” is increasingly the first-choice method in the treatment of nonhealing venous leg ulcers.

**Address for correspondence**

Hans Joachim HERMANN
Clinic for Vascular Medicine
Venous and Wound Care Center
Neue Linner Straße 86
47799 Krefeld
Germany

E-mail: hermanns@gefaessmedizin.info
www.phlebology.de

REFERENCES

- Hynes W. “Shaving” in Plastic Surgery With Special Reference To The Treatment Of Chronic Radiodermatitis. *Br J Plas Surg.* 1959;12:43-54.
- Quaba AA, McDowall RAW, Hackett EJ. Layered shaving of venous leg ulcers. *Br J Plast Surg.* 1987;40:68-72.
- Schmeller W, Gaber Y, Gehl HB. Shave therapy is a simple, effective treatment of persistent venous leg ulcers. *J Am Acad Dermatol.* 1998;39:232-234.
- Bechara FG, Sand M, Stücker M, et al. Shave Therapy for Chronic Venous Ulcers: A Guideline for Surgical Management and Postoperative Wound Care. *Plastic Surgical Nursing.* 2006;26:29-34.
- Popescu M, Haug M. Eine einfache und effektive Behandlung des persistierenden venösen Ulcus cruris. *Vasomed.* 2003;15:62-65.
- Obermayer A, Göstl K, Walli G, Benesch T. Chronic venous leg ulcers benefit from surgery: long-term results from 173 legs. *J Vasc Surg.* 2006;44:572-579.
- Vuerstack J, Vainas T, Wuite J, et al. State-of-the-art treatment of chronic leg ulcers: a randomized controlled trial comparing vacuum-assisted closure (V.A.C.) with modern wound dressings. *J Vasc Surg.* 2006;44:1029-1037.



Amniotic membrane: An innovative treatment of refractory vascular ulcers?

Francis PESTEIL*
Mireille DROUET**
Marie-Claire ROUSANNE***
Philippe LACROIX*

* *Service de Chirurgie Thoracique, Cardio-Vasculaire et Angiologie, CHU Dupuytren, Limoges, France*

** *Service d'Immunologie, CHU Dupuytren, Limoges, France*

*** *Etablissement français du sang Aquitaine-Limousin*

ABSTRACT

Mixed arterial and venous ulcers often heal poorly if there is no revascularization, as observed in the elderly, diabetics, and chronic renal failure patients who often have diffuse, distal, and calcified vascular lesions. Treatment therefore is based on optimized local wound care, pain control, and management of the risk of infection inherent in these types of patients with chronic wounds.

Current avenues of research in treatment are based on the development of angiogenesis and the use of growth factors to promote healing. Placental tissue is known to contain a large quantity of growth factors. Use of the latter was indirectly reported by Davis in 1910 and Sabella in 1913, who described the use of fresh amniotic membrane (AM) in the management of chronic wounds occurring in the aftermath of burns.^{1,2} Since then, many studies have reported the use of placental tissue or AM in the management of chronic wounds. Currently, AM is used after freezing in the management of corneal defects.

The aim of this article is to provide an updated literature review of this technique and its therapeutic prospects in the management of refractory vascular ulcers.

INTRODUCTION

Vascular ulcers are the leading cause of chronic skin changes in the industrialized world. Venous disease is the cause of 60% to 80% of such ulcers; 10% are purely arterial and 20% to 30% are mixed arterial/venous ulcers.³

Many studies have reported epidemiological data and the therapeutic management of venous ulcers. Few studies of arterial or mixed ulcers are currently available, yet, with the aging of the population, such ulcers are increasingly common. Their prevalence is at least 1% in subjects over age 65 years^{4,5} and approximately 1.41 per thousand in the general population.⁶⁻⁸

Keywords:

ulcer, amniotic membrane, healing

Revascularization is not always feasible because of the diffuse, distal features of vascular lesions in the elderly and frequent comorbidity factors, which can contraindicate surgical management. In spite of the development of many types of wound dressings, healing of such ulcers is often difficult to achieve and the diagnosis of peripheral arterial disease is not always established. Current avenues of research are directed at cell therapy and the use of growth factors to promote angiogenesis and the healing process. Some studies have reported that autologous stem cells and growth factors stimulate angiogenesis, suggesting a possible approach to healing in the event of chronic skin changes.

The placenta naturally contains high amounts of growth factors and was used in healing ointment formulations up to the 1980s. It continues to be used successfully for healing purposes in some countries such as India. For reasons related to bacterial and viral safety, it is no longer used. Davis in 1910 and Sabella in 1913 reported the value of placenta in healing.^{1,2} In 1980, Bennett, Matthews, and Faulk reported the use of fresh AM in the management of leg ulcers as a preparation for skin grafting.^{9,10} Considering the risk of bacterial and, in particular, viral infection, these techniques have not been developed.

However, AM can be frozen and serologically tested, thus enabling its possible use in therapeutic management. Currently, AM is used successfully in ophthalmology,^{11,12} and its use could perhaps be extended to the treatment of chronic skin changes, in particular arterial or mixed vascular ulcers. Here we provide an update on this therapy and its indications, mechanisms of action, and potential advantages in healing of ulcers, by means of a literature review and the authors' own preliminary study.

MATERIAL

AM is histologically analogous to cutaneous tissue, and according to some authors is a fetal derivative of ectoderm.¹³ It consists of a cuboidal cell epithelium and a stroma resting on a basement membrane. It has no nerves, blood vessels, or lymphatics. AM expresses few antigens, which accounts for its good tolerability and the absence of rejection reactions.¹⁴

Becchetti et al reported AM's high glycosaminoglycan content and that it contains hyaluronic acid, chondroitin

sulfate, dermatane sulfate, and heparan sulfates.¹⁵ Their role in healing is now established, in particular that of hyaluronic acid, which is present in large quantities in fetal tissue and can produce complete healing.

Several authors have reported that AM may have bacteriostatic or bactericidal activity. Matthews et al reported a decrease in bacterial contamination of wounds treated with AM.¹⁶ Some authors consider that the bacteriostatic properties may simply be linked to the protective action of the membrane itself.^{14,17} Others believe that proteins such as allantoin, immunoglobulins, and lysozyme may be involved.¹⁸

Faulk et al have reported the benefits of AM in wound management.¹⁰ Histological analysis of leg ulcers before and 5 days after treatment with AM revealed an increase in granulation tissue and in connective tissue, formation of basement membrane, and vascular development. Increased expression of factor VIII synthesized by endothelial cells was also observed.¹⁰ Somerville has reported the formation of capillary neovessels following use of AM after storage at 4°C.¹⁸ AM expresses many neurotrophic and angiogenic factors: endothelins 2 and 3, vascular endothelial growth factor (VEGF), VEGF-B, Tie-2 angiopoietin receptor, ephrin-A2, ephrin receptors A2, B1, B3, B4, B5, neuropilin-2, nerve growth factor (NGF) receptor, and semaphorin-F¹⁹ as well as erythropoietin and its receptor.^{20,21}

Histology studies of the cornea treated with AM indicate that the AM is resorbed, except for its basement membrane from which the cornea re-epithelializes, without a stromal, vascular, or inflammatory reaction.²² In summary, literature reports indicate that AM promotes healing by facilitating the formation of granulation tissue, an antibacterial action, and an anti-inflammatory and analgesic action, without any evidence of rejection because the immunogenicity of AM is low.²³

Currently, human AM is prepared from placenta obtained after scheduled delivery by cesarean section following a normal pregnancy. One placenta can provide 40 to 50 AM tissue fragments 5 cm in diameter. Currently, five centers in France process AM, each using its own techniques.

In our center, preparation is performed in a classified (class D) room with a microbiological safety workstation

(class A), within 2 hours of a cesarean section delivery. The placenta is left in contact for 2 hours with an antibiotic solution in its collection container and is then rinsed with physiological saline and the AM is separated from the lamina propria and dissected. Nitrocellulose disks are placed on the membrane and the operator cuts around the disk. Thus, AM tissue fragments about 5 cm in diameter are obtained.

The membrane and the disk are rolled up and the entire structure is immersed in a sterile immediate packaging tube. This tube contains a cryoprotective agent (RPMI and glycerol). The primary tube is inserted into a secondary tube which also is sterile. Each tube is packaged in a hermetically sealed plastic bag. The product is stored in the freezer at a temperature of -80°C for up to 2 years (*Figures 1 and 2*).

Three AM samples are collected for bacteriological examination. The placenta rinse fluid (8 to 10 mL) is used to inoculate 2 vials of aerobic and anaerobic organisms for bacteriological tests. The placenta is prepared for a pathology examination.

On the day of the cesarean section, test tubes containing blood from the mother are collected for the following serology tests: HIV 1 and 2: 2 tests, Ag p24, HCV, HTLV, syphilis: VDRL-TPHA, HBV: HBs antigen-HBc antibody. Final validation of the AM is performed after a repeat serology test by summoning the woman donor after 120 days.

AM is obtained on a doctor's prescription, and kept on dry ice for transport. AM can be stored on dry ice for 24 hours and conserved 2 hours before utilization after thawing.



Figure 1: Processing of amniotic membrane.

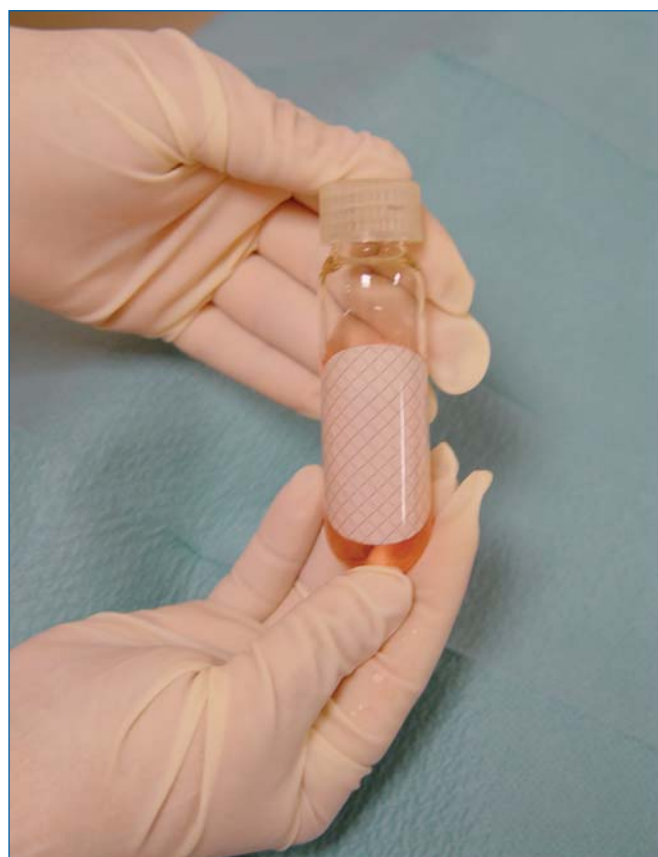

Figure 2: Amniotic membrane in its preserving fluid

RESULTS

The use of AM in wound healing has been reported in the literature for almost a century,^{1,2} and its safety and excellent tolerability appear established: to date, no study has reported any episode of intolerance or allergy, probably because of its low immunogenicity.^{14,22}

The usefulness of AM in wound healing is based on several mechanisms of action. First, AM acts as a dressing and isolates the wound, thus limiting the loss of protein and fluid and providing a medium that is conducive to healing. AM's bacteriostatic action may result from this protective property and also from the expression of proteins with antibacterial activity, such as allantoin, lysozyme, and immunoglobulins.^{14,16,17,19} AM promotes healing and possibly angiogenesis also.^{10,18,21,23}

AM has been studied in clinical practice with different types of wounds, such as burns, venous ulcers, radiation lesions, and arterial ulcers. Few clinical studies have been conducted on leg ulcers. The literature contains reports mainly on results obtained in ophthalmology.

Egan et al reported a study on 18 patients with venous ulcers of at least 8 years' duration and treated with AM in preparation for skin grafting. Treatment with fresh AM shortened the time before skin grafting from 24.9 to 10.7 days by improvement of granulation tissue and vascularization of ulcers. An analgesic action was also noted. On the other hand, the rate of recurrence and delay to recurrence of an ulcer did not improve after prior treatment with AM.²⁴

Ward et al demonstrated the optimization of skin grafting for venous ulcers after wound preparation with AM.²⁵ But the results appeared to vary depending on the methods of use and storage of AM. Thus, the skin graft failure rate was 6.3% when lyophilized AM was used, 11% with fresh amnion, and 25% when used after refrigeration. Mean healing time after skin grafting was also improved by preparation with AM, but depended on the storage method. Thus, mean time to healing was 22 days with lyophilized AM, 25 days with refrigerated AM, and 27.9 days with fresh amniotic membrane.²⁵

Pretreatment of venous ulcers with AM prior to skin grafting did not seem to have an impact on the subsequent outcome of these ulcers after they healed, since the recurrence rate was estimated at 50% at one year.²⁶

Hernandez et al reported efficacy in terms of healing in a heterogeneous group of patients with chronic wounds including burns, eschars, and venous ulcers. Fresh AM appeared beneficial, especially for eschars and burns.²⁷ Encouraging results were noted in another study in 15 patients with arterial ulcers: one patient underwent amputation and 14 patients improved with local wound care performed with AM, with complete healing in 8.⁹ Analgesic and bacteriostatic actions were also observed after treatment of postthrombotic venous ulcers with AM used after storage at 4°C.²⁸

In a preliminary study, we offered local wound care with frozen AM to 8 patients (7 men, 1 woman; mean age 69.5±9.6 years) with refractory vascular ulcers. Three patients had previously undergone arterial revascularization as well as treatment with wound dressings containing autologous keratinocytes (Epibase®) without improvement in their ulcers. Of the 8 patients, 4 had arterial lesions and 4 mixed ulcers. Mean ankle brachial pressure index was 0.62 ± 0.24 (0.3 to 1). Transcutaneous oxygen pressure at baseline and after

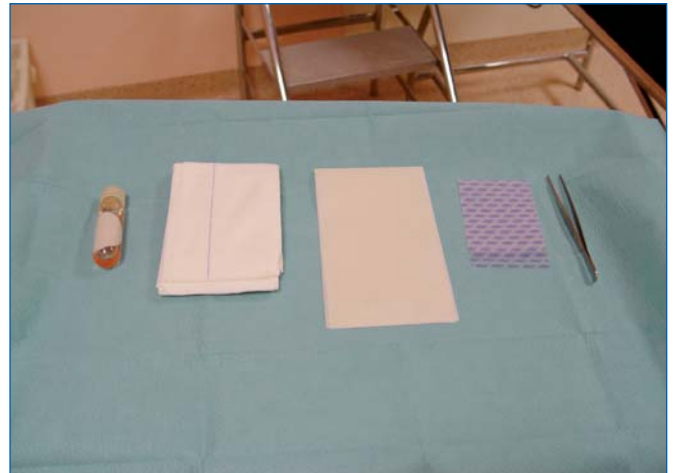


Figure 3: Preparation of the amniotic membrane and the wound dressing interface before placement of a wound dressing.

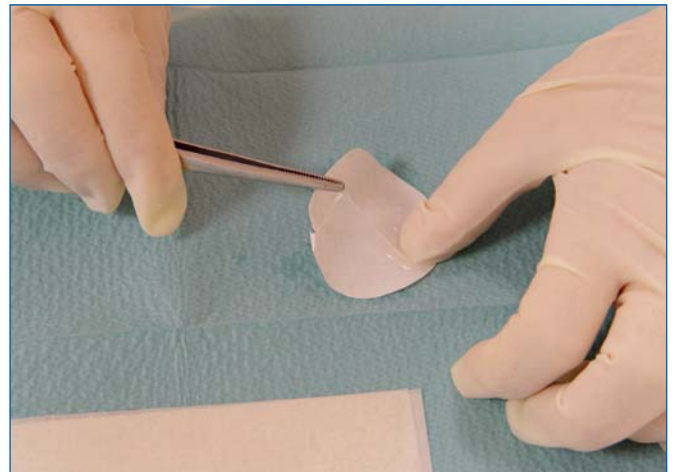

Figure 4: Amniotic membrane

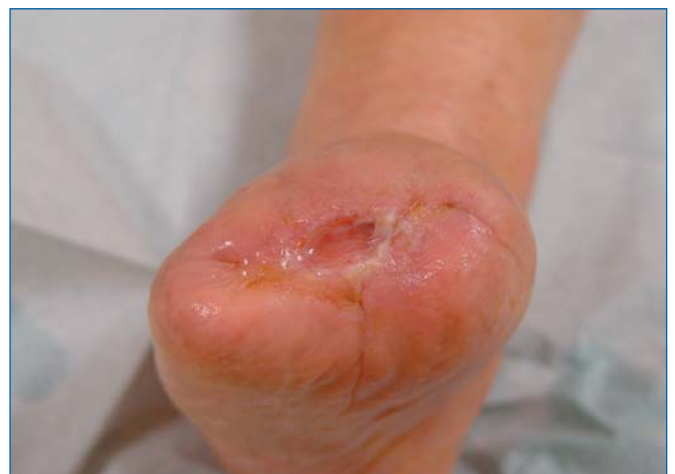

Figure 5: Application of the amniotic membrane to the wound.

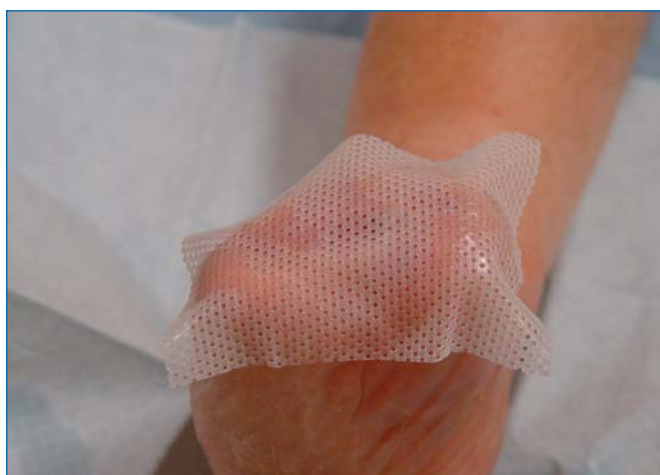

Figure 6: Application of a supporting interface

stimulation was 34 ± 17 (1 to 64) mm Hg and 47 ± 16 (26 to 74) mm Hg, respectively. The lesions were of at least 6 months' duration. AM was placed in contact with the ulcer and held in place with secondary dressings; the former was changed once a week and the latter three times (Figures 3 to 8).

Complete wound healing was obtained in 2 patients after 19 and 26 weeks (Figures 9 and 10). Reduction in wound size of at least 50% was obtained in another 3 patients after 26, 31, and 32 weeks. One patient improved, but with no major reduction in wound area after 14 weeks. Two patients did not improve with this treatment.

No patient presented with intolerance or an adverse event after application of the AM. No patient presented

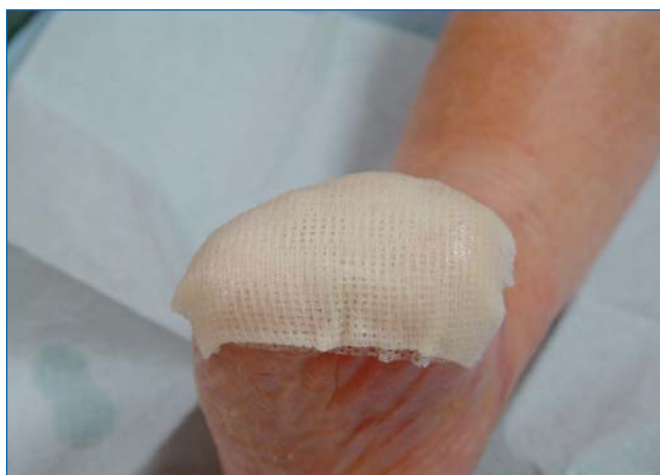

Figure 7: Application of an oily interface

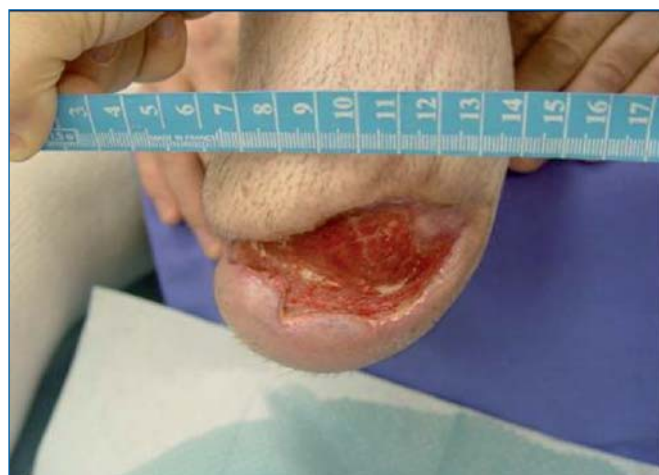

Figure 9: Delayed healing in a patient with peripheral arterial disease: stump wound 6 months after leg amputation

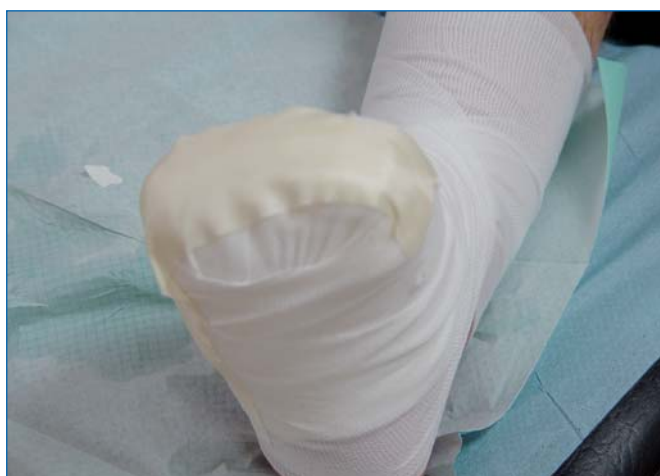

Figure 8: Securing of amniotic membrane and the interface with a bandage

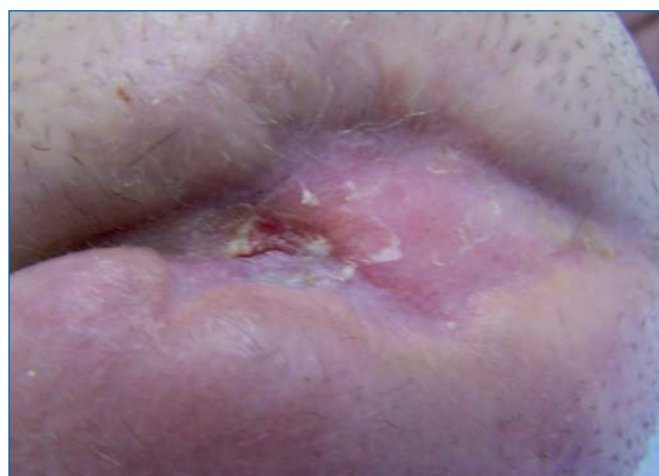


Figure 10: Outcome after 18 weeks of treatment with AM of the amputation stump

with an infectious complication or an inflammatory syndrome during the duration of this treatment. No patient required antibiotic therapy. No patient underwent an amputation.

One of the patients who had complete healing presented with an ulcer recurrence after the end of treatment.

An analgesic effect was observed in 7 patients. The mean visual analogue score decreased from 4 at D0 to 1 at D90 ($P=0.018$).

Evaluation of the SF-36 quality of life questionnaire demonstrated a significant improvement in the perception of general health ($P=0.01$), a benefit for "relations with others", which was at the limit of significance, as well as a benefit in "physical pain" ($P=0.13$),²⁹ which was also at the limit of significance.

DISCUSSION

Literature data seem to establish the tolerability and safety of AM in ophthalmology, where it is commonly used to treat thermal or chemical burns, eye injury in Stevens-Johnson syndrome, and pemphigoid, and is also used in pterygium surgery and limbic transplantation,³⁰ but also in the management of vascular leg ulcers. This excellent tolerability is probably related to its low immunogenicity, which is due to its low expression or nonexpression of the major histocompatibility complex antigens.²⁰

The usefulness of AM lies in its analgesic and bacteriostatic actions, as reported in several studies, and this was true regardless of the method of preparation, ie, fresh, refrigerated, or frozen AM.

AM also has anti-inflammatory properties which can prove useful in the management of chronic wounds where there is often an imbalance between proteases and antiproteases. In fact, AM expresses an interleukin-1 receptor antagonist, inhibitors of metalloproteinases 1,2, 3 and 4, and interleukin 10.²⁰

Recent studies suggest that amniotic epithelial cells may have plasticity allowing differentiation into ecto-, meso-, or endodermal cells. In fact, they express common markers found on pluripotent stem cells, and can differentiate into hepatocytes, cardiac cells, and neurons.^{20,30,31} Their use for therapeutic purposes to

regenerate tissues does not raise any ethical issues as with embryonic stem cells, since placental tissue is taken to be a byproduct of surgery.

The pro-angiogenic effect of AM is currently debated and it is unlikely that any such effect is involved in wound healing. Some ophthalmology studies have even suggested an anti-angiogenic action.³²

AM is subject to traceability requirements and serological testing to ensure its safety for use in clinical practice. Freezing allows optimized storage and improves availability of AM. This method of storage preserves cell viability as well as the properties of growth factors and cytokines.³¹ New methods for storage of AM are now under evaluation. These involve infrared and microwave drying processes and sterilization with gamma radiation, which has the advantage of allowing extended storage at room temperature. Clinical studies are necessary to evaluate the efficiency of AM treated this way.²⁰

AM promotes healing of injuries to the cornea, which is fragile tissue because of its fine blood vessels. Some studies suggest that AM promotes healing of chronic wounds, in particular venous or arterial vascular ulcers. However, such studies are often prospective, patients were not randomized, and patient populations are poorly defined and heterogeneous. Furthermore, most studies are old and report the use of fresh AM, AM refrigerated at 4°C or -25°C, or AM lyophilized and sterilized with gamma radiation.^{17,19,25} Currently, AM is used after freezing at -80°C. In this form, results are only available in ophthalmology. Few studies have examined the clinical utility of AM in the management of chronic wounds, in particular vascular ulcers. No study has reported poor tolerability or an increased risk of infection associated with AM.

Prospective studies on groups of homogeneous patients are necessary to establish the potential benefit of AM in the healing of vascular ulcers. Dissemination of this method will most probably be limited by the cost and availability of AM.

CONCLUSION

Management of chronic wounds using AM has a long history, but was abandoned because of the risk of bacterial and viral infection. AM can now be made safe for use by current methods of processing by freezing, and

bacteriological and serological testing. AM is well tolerated when used for wound coverage, limits the risk of infection, and also has analgesic and anti-inflammatory actions. AM has proved valuable in ophthalmology in the healing of corneal wounds, but its healing properties in vascular ulcers and other chronic wounds remain to be evaluated by prospective studies in homogeneous groups of patients. Extension of the therapeutic use of AM will, however, be limited by cost and availability.

**Address for correspondence**

Francis PESTEIL
Thoracic Surgery, Cardiovascular
and Angiology Dpt
CHU Dupuytren
87000 Limoges
France

E-mail: francis.pesteil@chu-limoges.fr

REFERENCES

- Davis JW. Skin transplantation with a review of 550 cases at the Johns Hopkins Hospital. *John Hopkins Med J.* 1910;15:307-396.
- Sabella N. Use of the fetal membranes in skin grafting. *Medical Record.* 1913;15:478-480.
- Cornwall JV, Doré CJ, Lewis JD. Leg ulcers: epidemiology and aetiology. *Br J Surg.* 1986;73:693-696.
- Andersson E, Hansson C, Swanbeck G. Leg and foot ulcer prevalence and investigation of the peripheral arterial and venous circulation in a randomised elderly population. An epidemiological survey and clinical investigation. *Acta Derm Venereol.* 1993;73:57-61.
- O'Brien JF, Grace PA, Perry IJ, Burke PE. Prevalence and aetiology of leg ulcers in Ireland. *Ir J Med Sci.* 2000;169:110-112.
- Moffatt CJ, Franks PJ, Doherty DC, Martin R, Blewett R, Ross F. Prevalence of leg ulceration in a London population. *QJM.* 2004;97:431-437.
- Pina E, Furtado K, Franks PJ, Moffatt CJ. Leg ulcer in Portugal: an underestimated health care problem. *Rev Port Cir Cardiorac Vasc.* 2004;11:217-221.
- Baker SR, Stacey MC, Singh G, Hoskin SE, Thompson PJ. Aetiology of chronic leg ulcers. *Eur J Vasc Surg.* 1992;6:245-251.
- Bennett JP, Matthews R, Faulk WP. Treatment of chronic ulceration of the legs with human amnion. *Lancet.* 1980;31:1153-1155.
- Faulk WP, Matthews R, Stevens PJ, Bennett JP, Burgos H, His BL. Human amnion as an adjunct in wound healing. *Lancet.* 1980;31:1156-1157.
- Muraine M, Descargues G, Franck O, et al. Amniotic membrane graft in ocular surface disease. Prospective study with 31 cases. *J Fr Ophthalmol.* 2001;24:798-812.
- Von Versen-Hoyneck F, Hesselbarth U, Moller DE. Application of sterilised human amnion for reconstruction of the ocular surface. *Cell Tissue Bank.* 2004;5:57-65.
- Pigeon J. Treatment of second degree burns with amniotic membranes. *Can Med Assoc J.* 1960;83:844-845.
- Singh R, Chouhan US, Purohit S, et al. Radiation processed amniotic membranes in the treatment of non-healing ulcers of different etiologies. *Cell Tissue Bank.* 2004;5:129-134.
- Becchetti E, Pagliarini A, Evangelisti R, Negri P. Composizione in glicosaminoglicani della membrana amnio-coriale umana in condizioni normali e patologiche. *Boll Soc It Biol Sper.* 1981;57:829-834.
- Matthews RN, Bennett JP, Faulk WP. Amnion on wounds: A perspective. *Reprod Immunol.* 1981;269-280.
- Gajiwala AL, Sharma V. Use of irradiated amnion as a biological dressing in the treatment of radiation induced ulcers. *Cell Tissue Bank.* 2003;4:147-150.
- Somerville PG. L'utilisation de la membrane amniotique comme pansement biologique dans le traitement des ulcères chroniques de jambe. *Phlébologie.* 1982;35:223-229.
- Gajiwala K, Gajiwala AL. Evaluation of lyophilised, gamma-irradiated amnion as a biological dressing. *Cell Tissue Bank.* 2004;5:73-80.
- Toda A, Okabe M, Yoshida T, Nikaido T. The potential of amniotic membrane/Amnion-derived cells for regeneration of various tissues. *J Pharmacol Sci.* 2007;105:215-228.
- Marvin KW, Keelan JA, Eykholt RL, Sato TA, Mitchell MD. Expression of angiogenic and neurotrophic factors in the human amnion and choriondecidua. *Am J Obstet Gynecol.* 2002;187:728-734.
- Gris O, Wolley-Dod C, Güell J.L, et al. Histologic findings after amniotic membrane graft in the human cornea. *Ophthalmology.* 2002;109:508-512.
- Quinby WC, Hoover HC, Schefflan M, Walters PT, Slavin SA, Bondoc CC. Clinical trials of amniotic membranes in burn wound care. *Plast Reconstr Surg.* 1982;71:1-716.
- Egan TJ, O'Driscoll J, Thakar DR. Human amnion in the management of chronic ulceration of the lower limb: a clinico-pathologic study. *Angiology.* 1983;197-203.
- Ward DJ, Bennett JP, Burgos H, Fabre J. The healing of chronic venous leg ulcers with prepared human amnion. *Br J Plast Surg.* 1989;42:463-467.
- Ward DJ, Bennett JP. The long-term results of the use of human amnion in the treatment of leg ulcers. *Br J Plast Surg.* 1984;37:191-193.
- Hernandez Cañete CM. La membrana amniocorial en el tratamiento de las úlceras vasculares. *Angiología.* 1993;3:112-116.
- Shun A, Ramsey-Stewart G. Human amnion in the treatment of chronic ulceration of the leg. *Med J Aust.* 1983;2:279-283.
- Pesteil F, Oujaou-Faïz K, Drouet M, et al. Utilisation des membranes amniotiques cryopréservées dans la prise en charge des ulcères vasculaires rebelles. *J Mal Vasc.* 2007;32:201-209.
- Miki T, Strom SC. Amnion-derived pluripotent/multipotent stem cells. *Stem Cell Rev.* 2006;2:133-141.
- Parolini O, Alviano F, Bagnara GP, et al. Concise review: Isolation and characterization of cells from human term placenta: outcome of the first International Workshop on placenta derived stem cells. *Stem Cells.* 2008;26:300-311.
- Sippel KC, Ma JJ, Foster CS. Amniotic membrane surgery. *Curr Opin Ophthalmol.* 2001;12:269-281.



About new articles and books

Based on an original review: Kakkos SK, Caprini JA, Geroulakos G, Nicolaides AN, Stansby GP, Reddy DJ. Combined intermittent pneumatic leg compression and pharmacological prophylaxis for prevention of venous thromboembolism in high-risk patients. *Cochrane Database Syst Rev.* 2008, Issue 4. Art. No.: CD005258. DOI:10.1002/14651858.CD005258.pub2

Stavros K. KAKKOS¹
Joseph A. CAPRINI²
George GEROULAKOS³
Andrew N. NICOLAIDES⁴
Gerard P. STANSBY⁵
Daniel J. REDDY¹

¹ Division of Vascular Surgery, Department of Surgery, Detroit, USA

² Department of Surgery, Evanston Northwestern Healthcare, Evanston, USA

³ Vascular Unit and Department of Vascular Surgery, Ealing Hospital and Imperial College, London, Southall, UK

⁴ Vascular Screening and Diagnostic Centre, and Cyprus University, Nicosia, Cyprus

⁵ Department of Surgery, University of Newcastle upon Tyne, Newcastle upon Tyne, UK

A review by Stavros K. KAKKOS

Update Cochrane review on the prevention of venous thromboembolism.

SUMMARY

Introduction

Despite the use of contemporary prophylactic measures, the incidence of venous thromboembolism (VTE, defined as deep vein thrombosis [DVT] or pulmonary embolism [PE] or both) is still great especially in high-risk patients, including those undergoing total hip or knee replacement, or colorectal surgery for cancer. In an effort to intensify thromboprophylaxis, the consensus guidelines on this topic have recommended combined pharmacological and mechanical prophylaxis in high-risk patient groups. This suggestion is based on evidence that combined modalities (intermittent pneumatic leg compression and pharmacological prophylaxis) are more effective than single modalities (intermittent pneumatic leg compression or pharmacological prophylaxis) in preventing VTE in such patients. The enhanced efficacy of combined modalities is possibly the effect of intensified intervention on more than one element of Virchow's triad.¹ The aim of the present study was to review the efficacy of intermittent pneumatic leg compression combined with pharmacological prophylaxis compared with single modalities alone in preventing VTE in high-risk patients.

METHODS

Randomized controlled trials and controlled clinical trials of combined intermittent pneumatic leg compression and pharmacological interventions, used to prevent VTE in high-risk patients, were identified from the following databases: Cochrane Central Register of Controlled Trials database, the Specialized Register of the Peripheral Vascular Diseases Group (which contains citations of trials identified through electronic searches of MEDLINE and EMBASE), MEDLINE (through direct search). Hand searching of journals and conference proceedings was also performed. Data extraction was undertaken independently by two review authors (SKK & GG) using data extraction sheets.



THE COCHRANE
COLLABORATION®

RESULTS

Eleven trials including a total of 7431 patients were identified.²⁻¹² Six of them were randomized controlled trials^{4,6,7,9,10,12} that involved a total of 6273 patients.

1. Compression + anticoagulant versus compression

Six of the included studies evaluated the role of combined modalities on the incidence of symptomatic PE.²⁻⁷ Compared with compression alone, the use of combined modalities significantly reduced the incidence of PE (from about 3% to 1%; odds ratio [OR], 0.39; 95% confidence interval [CI], 0.25 to 0.63). Results did not demonstrate heterogeneity or publication bias ($I^2 = 0\%$). Four studies investigated the role of combined modalities on the incidence of DVT.^{2,5-7} Compared with compression alone, the use of combined modalities significantly reduced the incidence of DVT (from about 4% to 1%; OR 0.43, 95% CI 0.24 to 0.76). Results did not demonstrate heterogeneity or publication bias ($I^2 = 0\%$).

2. Compression + anticoagulant versus anticoagulant

Four studies investigated the impact of combined modalities on the incidence of DVT.^{2,8-10} Compared with pharmacological prophylaxis alone, combined modalities significantly reduced the incidence of DVT (from 4.21% to 0.65%; OR, 0.16; 95% CI, 0.07 to 0.34). Results were consistent and demonstrated moderate heterogeneity ($I^2 = 33\%$). Three studies evaluated the impact of combined modalities on the incidence of symptomatic PE.^{2,8,10} The incidence of PE was 0% in both the control group (0/214) and the treatment group (0/176), which indicates that the included studies were underpowered with regard to PE.

The comparison of compression plus pharmacological prophylaxis versus compression plus aspirin showed a nonsignificant reduction in PE and DVT in favor of the former group.^{11,12}

Repeat analysis restricted to the randomized controlled trials confirmed the above findings.

CONCLUSIONS

The results of the present meta-analysis show that, compared with compression alone, combined prophylactic modalities significantly decrease the incidence of VTE. Compared with pharmacological prophylaxis alone, combined modalities significantly reduce the incidence of DVT, but the effect on PE is unknown because the relevant trials were underpowered. The results of the current review support the use of combined modalities in VTE prevention, especially in high-risk patients, provided that specific contraindications for each method are not present. More studies on the role of combined modalities in PE prevention, compared with pharmacological prophylaxis alone, are urgently needed.




Address for correspondence

Stavros K. Kakkos
University of Patras Medical
School
Patras 26500
Greece

E-mail: kakkosstavros@gmail.com
s.kakkos@imperial.ac.uk
kakkos@upatras.gr

REFERENCES

1. Virchow R. Phlogose und thrombose im gefässsystem. In: Virchow R, ed. *Gesammelte Abhandlungen zur Wissenschaftlichen Medizin*. Frankfurt am Main, Germany: von Meidinger Sohn & Comp. 1856:458-636.
2. Bigg SW, Catalona WJ. Prophylactic mini-dose heparin in patients undergoing radical retropubic prostatectomy. A prospective trial. *Urology*. 1992;39:309-313.
3. Borow M, Goldson HJ. Prevention of postoperative deep venous thrombosis and pulmonary emboli with combined modalities. *Am Surg*. 1983;49:599-605.
4. Ramos R, Salem BI, De Pawlikowski MP, Coordes C, Eisenberg S, Leidenfrost R. The efficacy of pneumatic compression stockings in the prevention of pulmonary embolism after cardiac surgery. *Chest*. 1996;109:82-85.
5. Sieber PR, Rommel FM, Agusta VE, et al. Is heparin contraindicated in pelvic lymphadenectomy and radical prostatectomy? *J Urol*. 1997;158:869-871.
6. Turpie AGG, Bauer KA, Caprini JA, Comp PC, Gent M, Muntz JE; APOLLO Investigators. Fondaparinux combined with intermittent pneumatic compression vs. intermittent pneumatic compression alone for prevention of venous thromboembolism after abdominal surgery: a randomized, double-blind comparison. *J Thromb Haemos*. 2007;5:1854-1861.
7. Woolson ST, Watt JM. Intermittent pneumatic compression to prevent proximal deep venous thrombosis during and after total hip replacement. A prospective, randomized study of compression alone, compression and aspirin, and compression and low-dose warfarin. *J Bone Joint Surg Am*. 1991;73:507-512.
8. Bradley JG, Krugener GH, Jager HJ. The effectiveness of intermittent plantar venous compression in prevention of deep venous thrombosis after total hip arthroplasty. *J Arthroplasty*. 1993;8:57-61.
9. Eisele R, Kinzl L, Koelsch T. Rapid-inflation intermittent pneumatic compression for prevention of deep venous thrombosis. *J Bone Joint Surg Am*. 2007;89:1050-1056.
10. Silbersack Y, Taute BM, Hein W, Podhaisky H. Prevention of deep-vein thrombosis after total hip and knee replacement. Low-molecular-weight heparin in combination with intermittent pneumatic compression. *J Bone Joint Surg Br*. 2004;86:809-812.
11. Westrich GH, Rana AJ, Terry MA, Taveras NA, Kapoor K, Helfet DL. Thromboembolic disease prophylaxis in patients with hip fracture: a multimodal approach. *J Orthop Trauma*. 2005;19:234-240.
12. Westrich GH, Bottner F, Windsor RE, Laskin RS, Haas SB, Sculco TP. VenaFlow plus Lovenox vs VenaFlow plus aspirin for thromboembolic disease prophylaxis in total knee arthroplasty. *J Arthroplasty*. 2006;21:139-143.



FOAM SCLEROTHERAPY.

A textbook. John Bergan, Van Le Cheng (editors), Royal Society of Medicine 2008. ISBN 978-1-85315-771-4



Address for correspondence

Michel PERRIN
26, chemin de Décines
69 680 Chassieu
France

E-mail:
m.perrin.chir.vasc@wanadoo.fr

A review by Michel Perrin

Following the list of contributors, the two forewords and the preface of this hardcover book of 231 pages, the main text is divided into 3 parts: theory, practice, and special considerations, in 20 chapters.

It is noteworthy that two thirds of the authors—36 in total—are not from the USA, reflecting the fact that foam sclerotherapy was practiced earlier in Europe and Australia. Many authors are surgeons, which means that this foam sclerotherapy is no longer exclusively used by phlebologists. In other words, the practitioner who treats varicose veins has to master various techniques to give the patient the best possible treatment.

The first part of the book deals with the history and the guidelines for using sclerotherapy, and a fully illustrated chapter describes in detail the dermatologic manifestations of venous insufficiency. The second part is devoted to foam production and underlines the invaluable help provided by ultrasound investigation, including the postprocedure assessment. The third and last part mainly covers the indications for foam sclerotherapy in telangiectasias, large varicose veins, and recurrent varicose veins after treatment and vascular malformations (3 chapters). Besides the outcome of European randomized trials, a comparison of the efficacy of polidocanol versus sodium tetradecyl sulfate is reported. An original chapter underlines that the saphenous trunk, on which treatment was focused until now, can be spared in many cases, and that high ligation is no longer compulsory in all patients.

In summary this book is an outstanding review of our knowledge of foam sclerotherapy, backed up by more than 600 references.



Congress and conference calendar

DATES	CONGRESS	COUNTRY	CITY
23-25 April 2009	XVII NATIONAL CONGRESS OF THE SPANISH CHAPTER OF PHLEBOLOGY OF THE SEACV	Spain	Zaragoza
30 April-2 May 2009	MAYO CLINIC INTERNATIONAL VASCULAR SYMPOSIUM	Hungary	Budapest
8-9 May 2009	BENELUX SOCIETY OF PHLEBOLOGY	Belgium	Harzé
14 - 16 May 2009	18th CONGRESO ARGENTINO E INTERNACIONAL DE FLEBOLOGIA Y LINFOLOGIA	Argentina	Buenos Aires
28-30 May 2009	CONGRESS OF POLISH PHLEBOLOGICAL SOCIETY	Poland	Warsaw
5 - 7 June 2009	10th ANNUAL MEETING OF THE EUROPEAN VENOUS FORUM	Denmark	Copenhagen
18-20 June 2009	55 NATIONAL CONGRESS OF THE SPANISH SOCIETY OF ANGIOLOGY AND VASCULAR SURGERY	Spain	Valencia

CONTACT	SECRETARIAT	WEB SITE
Gerardo Pastor, MD <i>President of organizing committee</i>	Congresos XXI Gran Vía, 81 - 5º Dpto. 10 48011 Bilbao Phone no.: +34 94 427 88 55 Fax no.: +34 94 427 88 08 E-mail: info@congresosxxi.com	www.capitulodeflebologia.org
Peter Gloviczki, MD Haraldur Bjarnason, MD Raymond C. Shields, MD <i>Mayo Clinic Course Directors</i>		www.mayo.edu/cme/apr2009.html
		www.phlebologybenelux.org
Daniel Balboni <i>President</i>	E-mail: info@sociedadflebologia.com	www.sociedadflebologia.com/congreso.html
Szpital Bielański	Szpital Bielański ul. Cegłowska 80 01-809 Warszawa Phone no.: +48 22 56 90 285	www.ptf.org.pl
Niels Baekgaard, MD	E-mail: evenousforum@aol.com	
Manuel Miralles, MD <i>President of organizing committee</i>	Torres Pardo Nàpols, 187 2º 08013 Barcelona Phone no.: +34 93 246 35 66 Fax no.: +34 93 231 79 72 E-mail: m.velazquez@torrespardo.com (Sra. Meritxell Velázquez)	www.seacv2009.com www.seacv.es

CONGRESS

DATES	CONGRESS	COUNTRY	CITY
18-20 June 2009	IX CONGRESS OF THE PORTUGUESE SOCIETY OF ANGIOLOGY AND VASCULAR SURGERY	Portugal	Buenos Aires
4-5 July 2009	THE 8th NATIONAL CONGRESS OF ANGIOLOGY AND VASCULAR SURGERY WITH INTERNATIONAL PARTICIPATION	Romania	Warsaw
31 August-4 September 2009	XVI WORLD MEETING OF THE UNION INTERNATIONALE DE PHLEBOLOGIE (UIP)	Principality of Monaco	Copenhagen
19-22 September 2009	18th EUROPEAN CHAPTER CONGRESS OF THE INTERNATIONAL UNION OF ANGIOLOGY Join with XIX ANNUAL MEETING OF THE MEDITERRANEAN LEAGUE OF ANGIOLOGY AND VASCULAR SURGERY	Italy	Monaco
21-25 September 2009	22nd INTERNATIONAL CONGRESS OF LYMPHOLOGY	Australia	Palermo
21-25 April 2010	XXIV WORLD CONGRESS OF THE INTERNATIONAL UNION OF ANGIOLOGY (IUA)	Argentina	Palm Springs

CONTACT	SECRETARIAT	WEB SITE
<p>Joaquim Barbosa, MD <i>President</i> Armando Mansilha, PhD <i>General Secretary</i></p>	<p>Avenida João Crisóstomo, 30,5° 1050-127 Lisboa Phone no.: +351 21 33 03 72 09 Fax no.: +351 21 33 03 733 E-mail: spacv@sapo.pt</p>	<p>www.spacv.org</p>
<p>Aurel Andercou, PhD <i>President of the Romanian Society of Angiology & Vascular Surgery</i></p>	<p>Romanian Society of Angiology & Vascular Surgery Cluj Napoca, str. Clinicilor nr 2-4 Phone no.: +40 722 365 380 Fax no.: +40 264 597 523 E-mail: aurelandercou@hotmail.com</p>	<p>www.vascular.ro</p>
<p>Eberhardt Rabe, PhD <i>Chairman of scientific committee</i> Jean-Jérôme Guex, MD <i>Chairman of organizing committee</i></p>	<p>Publi Créations – Partner of AIM 27, boulevard d'Italie 98000 Monaco Phone no.: +377 9797 3555 Fax no.: +377 9797 3550 E-mail: uip2009@publiccreations.com</p>	<p>www.aim-internationalgroup.com/2009/uip</p>
<p>Claudio Allegra, PhD Salvatore Novo, PhD <i>Presidents of the 18th EUROCHAP Meeting</i> Pier Luigi Antignani, PhD Salvatore Novo, PhD <i>Presidents of the XIX MLAVS 2009 Meeting</i></p>	<p>AIM Group - AIM Congress Via Flaminia, 1068 00189 Rome Phone no.: +39 06 330531 Fax no.: +39 06 33053229 E-mail: eurochap2009@aimgroup.it</p>	<p>www.aimgroup.eu/2009/eurochap-mlavs</p>
<p>Neil Piller, PhD <i>President</i></p>	<p>E-mails: neil.piller@flinders.edu.au lymphology@icmsaust.com.au</p>	
<p>Salvatore Novo, PhD <i>President</i></p>	<p>Ana Juan Congresos Malasia 884 (C1426BNB) Buenos Aires Phone no.: +54 11 4777 9449 Fax no.: +54 11 4777 2880 E-mail: celia@anajuan.com</p>	<p>www.iaa2010.com.ar</p>

More information on Venous or Lymphatic Diseases?



The screenshot shows the homepage of the Phlebology website. At the top, there is a navigation menu with links for Editorial Board, Latest Issue, Phlebology by topic, Special Issues, and Events. Below the menu, a banner features the Phlebology logo and the text: "Phlebology is an international scientific journal entirely devoted to venous and lymphatic diseases." The main content area is divided into sections: "Aim and scope" which describes the journal's focus on providing updated information to doctors; "Download the last issue" with a link to click here; "Latest Events" listing the XIXth annual congress of the American College of Phlebology (10-11.05) and the XIXth congress nazionale collegio italiano di flebologia (13.10.05); and "Web sites of interest". The footer contains contact information, a site map, legal info, credits, and a copyright notice for 2004 Les Laboratoires Servier.

>>> Go to
www.phlebology.org

What is Phlebology?

Events

Editorial Board

Special issues

Latest issue

Latest events

Download the last issue

Web sites of interest

Phlebology per topic

- CEAP classification
- Chronic venous disease
- Chronic venous insufficiency
- Deep venous surgery
- Deep venous thrombosis
- Edema
- Hemorrhoidal disease
- Investigation in venous and lymphatic disease
- Lymphedema
- Pelvic varicose veins and congestion syndrome
- Plebotonic drug
- Postthrombotic syndrome
- Venous and lymphatic pathophysiology
- Thromboembolic disease
- Venous malformations
- Varicose vein (surgery)
- Varicose vein (sclerotherapy)
- Venous anatomy and pathology
- Venous aneurysms
- Venous ulcer
- Venous physiology
- Special congress issues

How to publish?